

# Odontome Associated with a Mesiodens: A Rare Case Report

## Abstract

Odontomas are most common odontogenic benign tumors composed of dental tissue. Most of these lesions are asymptomatic and are often detected on routine radiographs. Odontomas are considered to be developmental anomalies rather than true neoplasms. Odontome have been termed as compound composite odontomas when there is at least superficial anatomic similarity to normal teeth. A supernumerary tooth in the maxillary anterior region is termed a mesiodens. This case report presents an unusual case of occurrence of a compound composite odontome along with a mesiodens and also an erupted permanent central incisor in a 15 year old boy.

## Key Words

Nose; nasal bone; rhinion; point A; cephalometrics

Rashi Yadav<sup>1</sup>, Saba Tiwari<sup>2</sup>, Sachin Thakur<sup>3</sup>, Gagan Randhawa<sup>4</sup>

<sup>1</sup>Senior Lecturer, Department of Oral & Maxillofacial Surgery, Modern Dental College & Research Centre, Indore, Madhya Pradesh, India

<sup>2</sup>Post Graduate Student, Department of Oral & Maxillofacial Surgery, Modern Dental College & Research Centre, Indore, Madhya Pradesh, India

<sup>3</sup>Post Graduate Student, Department of Oral & Maxillofacial Surgery, Modern Dental College & Research Centre, Indore, Madhya Pradesh, India

<sup>4</sup>Post Graduate Student, Department of Oral & Maxillofacial Surgery, Modern Dental College & Research Centre, Indore, Madhya Pradesh, India

## INTRODUCTION

The term odontoma (or odontome) was originally used by Paul Broca in 1867 to describe all odontogenic tumors. Presently this term is circumscribed to benign lesions of odontogenic origin and a mixed character composed of, dental epithelial and mesenchymal cells. Due to their composition and behavior, odontomas can be regarded as hamartomas or malformations rather than true neoplasms. These malformations do not develop further once fully calcified but, like teeth, they may erupt into the mouth. This is, however, a rare situation. They are characterized by their slow growth and non-aggressive behavior.<sup>[1]</sup> According to the 1992 classification of The World Health Organization (WHO), odontomas are classified as compound odontomas or complex odontomas. The odontoma is the most common odontogenic tumor in maxilla, and investigators report the incidence as 22-67% of all odontogenic maxillary neoplasms. Most compound odontoma are found in the upper incisors and canines areas, followed by the antero- and postero-inferior regions. Complex odontomas are commonly found in the areas of the second and third lower molars.<sup>[2]</sup> A Mesio dens is the most common supernumerary tooth and is located in the

palatal midline between two the maxillary central incisors. Some odontomas are associated with a history of trauma during primary dentition, as well as with inflammatory and infectious processes, hereditary anomalies. Odontomas generally appear as small, solitary or multiple radiopaque lesions detected during routine radiographic examination that may cause disturbances in tooth eruption, such as impaction, delayed eruption or retention of primary teeth.<sup>[3]</sup>

## CASE REPORT

A 15 year old male patient came with a complaint of an extra tooth present in the upper tooth region. On clinical examination, a supernumerary tooth between 11 and 12, located palatally (Fig 1). On radiographic examination, a mesiodens was seen associated with a radio-opaque lesion giving an appearance of a crown enclosed in a radiolucent capsule suggestive of follicle (Fig 2). A provisional diagnosis was made of odontome situated between 11 and 12. Patient did not complain of any pain or symptoms of parasthesia. He was only concerned about the extra tooth visible. After the completion of obturation of intentional root canal treatment for 21, the associated tooth, to ensure the security of the tooth, patient was prepared for surgical excision of

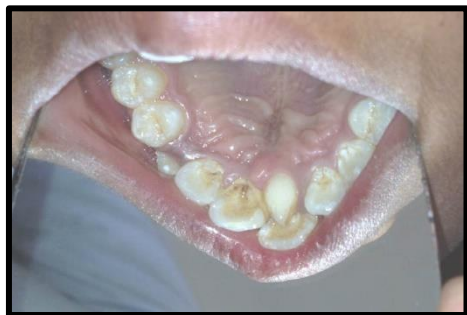

Fig. 1: Mesiodens between 11 and 21

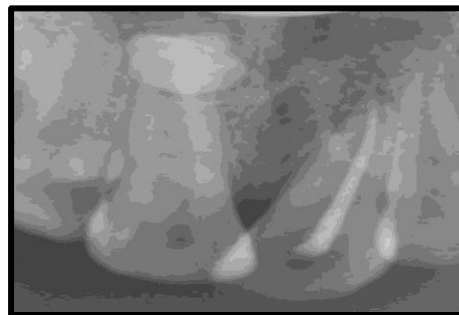


Fig. 2: IOPA showing mesiodens and the odontoma

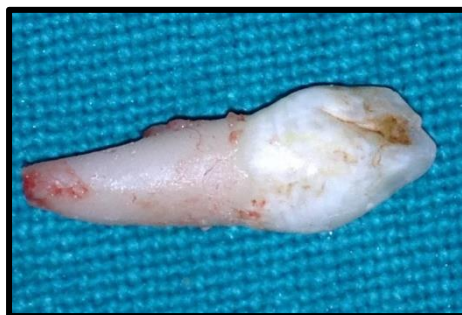

Fig. 3: Extracted mesiodens

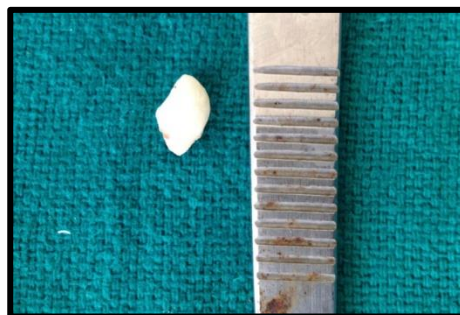

Fig. 4: Excised lesion

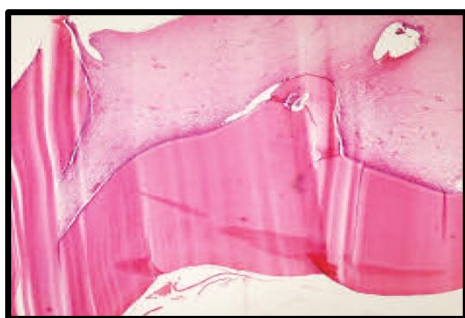


Fig. 5: Histopathologic view

tooth, patient was prepared for surgical excision of the lesion associated with the tooth. A radiograph with the SLOB technique was helpful in diagnosis of the palatal position of the lesion. A palatal mucoperiosteal flap was reflected after giving local anaesthetic block with adrenaline. Unusually, no bulge was found on the palatal bone. The mesiodens was extracted (Fig. 3) and using a round bur, the lesion was located in the bone. Bone was removed exposing the lesion and complete excision and curettage of the lesion was done with the attached follicle using a curette (Fig 4). This was followed by copious irrigation of the bony defect with betadine and saline solution to remove the debris. Retrograde cavity preparation followed by filling with MTA was done. Closure with mersilk suture of the flap was done, which were removed after 7 days. The excised lesion was sent for histopathologic investigation and was diagnosed as compound composite odontoma (Fig 5).

## DISCUSSION

Odontomas are relatively common, asymptomatic odontogenic lesions, rarely diagnosed before the second decade of life. The most frequent clinical signs are delayed eruption, persistence of the temporal tooth, and the presence of a tumor. In severe cases, infection or regional adenopathies may be observed.<sup>[4]</sup>

According to the WHO classification, odontomes can be divided into three groups

- Complex odontomes: When the calcified dental tissues are simply arranged as an irregular mass, bearing no morphological similarity to the rudimentary teeth.
- Compound odontomes: Composed of all odontogenic tissues in an orderly pattern that result in many teeth-like structures, but without any morphological resemblance to normal teeth.
- Ameloblastic fibro-odontomes: Consist of varying amounts of calcified dental tissues and dental papilla-like tissue, the latter component resembling an ameloblastic fibroma. The ameloblastic fibro-odontome is considered to be an immature precursor of a complex odontoma.<sup>[5]</sup>

Radiologically, the compound odontoma appears as a collection of tooth-like structures while appearance of complex odontomas depends on their stage of development and the degree of mineralization. The first stage is characterized by radiolucency due to lack of calcification. Partial

calcification is observed in the intermediate stage, while in the third stage, the lesion usually appears radiopaque.<sup>[6]</sup> Microscopic features show the denticles of compound odontomas comprise a central core, similar to pulp tissue, surrounded by primary dentin and covered with partially demineralized enamel and primary cement. Complex odontomas show primary or immature dentin as the predominant component, though enamel is also found, exhibiting two possible types of distribution.<sup>[7]</sup> In a clinical setting, an odontoma should be removed because it contains various tooth formulation that can predispose to cystic change, interfere with tooth eruption, cause considerable bone expansion. Usually, surgical treatment of odontoma is conservative and curative with no possibility of recurrence, if, the lining epithelium is removed intact.<sup>[8]</sup>

### CONCLUSION

A rare case of compound odontomas has been reported. The most important and interesting feature in this case was that the odontomas was associated with mesiodens and erupted maxillary incisor. A surgical intervention was done and the odontomas were extracted and further endodontic treatment was followed for the patient.

### REFERENCES

1. Salgado H, Mesquita P. Compound Odontoma - a case report. Portuguese Stomatolgy, Dentistry and Maxillofacial Surg 2013;54(3):161-5.
2. Lee CH, Gyeong Ju. Complex and compound Odontomes are clinico-pathological entities. Basic and Applied Pathology 2008;1:30-3.
3. de Andrade Santos PP, Barroso KMA, de Souza LB. Odontomas: Clinicopathologic study of 104 cases and a case report of compound odontoma associated in an unerupted maxillary central incisor in ca child. International Dentistry - African 2004;2(5).
4. Shredharan SP, Krishnan Is. Compound odontoma associated with impacted maxillary central incisor. Journal Of Indian Society Of Pedodontics and Preventive Dentistry 2012;3.
5. Meerkamal, Rowe J. L1. Williams; Maxillofacial Injuries, London.
6. Saito DM, Murr AH. Internal fixation of mandibular angle fractures with the Champy's. Operative Techniques in Otolaryngology 2008;19:123-28.