

Customized Mould Brachytherapy Appliance: A Boon for the Radiotherapy Patients

Abstract

Radiation therapy is the therapeutic use of ionizing radiation and can be applied via external beam or brachytherapy. Mould brachytherapy is short distance radiation delivery via custom fabricated carrier device known as mould. This report describes the fabrication of customized brachytherapy appliance for a 75yr old patient having carcinoma of left buccal mucosa and retromolar pad area.

Key Words

Brachytherapy; mould brachytherapy appliance; catheters; carcinoma of buccal mucosa and retromolar pad area

Suresh Kumar SK¹, Rachana KB²,
Vishnu Pratap Singh³, Ashok Galav⁴

¹Senior Lecturer, Department of Prosthodontics
Government Dental College & Research
Institute, Bellary, Karnataka, India

²Reader, Department of Prosthodontics,
Government Dental College & Research
Institute, Bellary, Karnataka, India

³Senior Lecturer, Department of Conservative
& Endodontics, KM Shah Dental College,
Vadodra, Gujarat, India

⁴Senior Lecturer, Department of Oral
Medicine, Diagnosis and Maxillofacial
Radiology, Tatyia Saheb Kore Dental College
and Research Centre, Kolhapur, Maharashtra,
India

INTRODUCTION

Brachytherapy is a method of radiation treatment in which sealed radioactive sources are used to deliver the dose a short distance by direct insertion into the tissue (interstitial), placement within a cavity (intracavitary) or surface application (molds).

CASE REPORT

A 75yr old female patient who reported to the Medical College Hospital, VIMS, Bellary, India with a history of long standing ulcer on the left buccal mucosa and retromolar pad area. On clinical examination an ulcer was seen on the left lateral aspect of the buccal mucosa measuring about 4x3cm in dimension and retromolar pad area with 2 palpable left submandibular lymph nodes. Biopsy and histopathological finding's confirmed a well differentiated squamous cell carcinoma with nodal metastasis. The patient was staged as T₄N₁M₀. After external beam radiotherapy; surface mould brachytherapy was planned and referred to Department of Prosthodontics, Government dental College, Bellary, India for the fabrication of customized brachytherapy applicator (Mould).

Fabrication of customized brachytherapy mould

Patient was asked to rinse his mouth with betadine solution before making the impression. Left buccal mucosa and retromolar pad area was the area to be

irradiated. As there were no teeth present between the lateral border of the tongue and buccal mucosa, the impression and the mould has to be stable and displace the buccal mucosa and the tongue away from the area to be irradiated. The position of the after loading catheters was determined by the radiation oncologist and was secured in place on the stone cast with sticky wax. Auto polymerizing acrylic resin was adapted to form a template to hold the catheter in position. After curing the rough edges were smoothed and polished. This template was inserted into the patient's mouth and silicone rubber base impression material was adapted on both the lateral and superior aspects to obtain an adequate thickness so as to displace the normal tissues away from the radiation site and stabilize the template while still maintaining the comfort of the patient. Before brachytherapy began, the template (Fig. 2) was inserted into the patient's mouth and the excess material was trimmed to ensure the stability of the mould throughout the treatment procedure. The appliance was positioned in the patient's mouth with dummy sources for simulation, and the final dosimetry was calculated by the radiation therapist. The appliance was after loaded with cobalt 60 remote after loading HDR Brachytherapy unit.

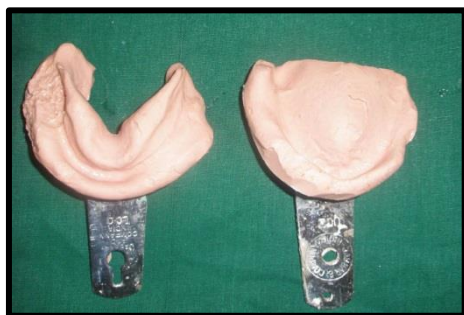

Fig. 1: Alginate impressions of maxillary and mandibular arches

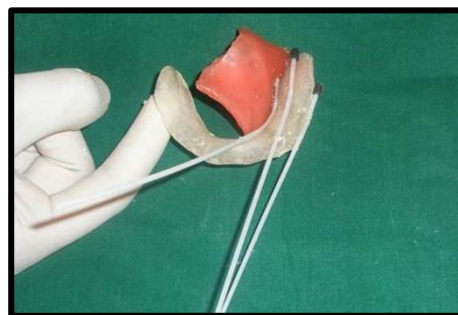


Fig. 2: Acrylic template with the catheters

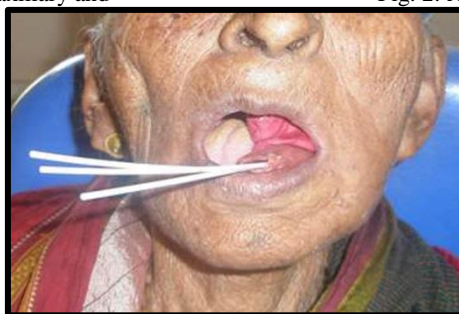

Fig. 3: Customized brachytherapy appliance

DISCUSSION

Oral carcinomas accounts for 5-7% of all carcinomas. In addition to the everlasting potential patient population being treated surgically, the use of radiotherapy, chemotherapy, and cryosurgery is now more common among the adjunctive forms of treatment used in the management of head and neck carcinomas. Brachytherapy is an important treatment modality available to clinicians for the management of patients with oral cancers. The advantages of this strategy is that surgery is avoided, thereby preserving the normal structure and function of the oro-masticatory complex. A rapid fall of dose around the radioactive source making it possible for increased tumor control while sparing the surrounding tissue and a short overall treatment duration which reduces the risk of tumor repopulation. During this short span, it is important that the catheter remain in the exact position determined by the radiation oncologist.

Dose and Duration of Radiotherapy

For this patient external beam radiotherapy of 50Gy was planned in 25 fractions. The dose was divided as 200cGy for 5days a week. The total duration of treatment was 5 weeks. This took care of the gross tumor and lymph nodes after which brachytherapy were planned. Dose of brachytherapy was 16Gy in 4 fractions. The dose was divided as 4Gy/fraction in 6 hrs gap and treatment duration was 24 hrs.^[4] The main advantage is the short duration period. During this short span, it is important that the catheter remain in the exact position determined by the

radiation oncologist. Earlier gauze compressors were used which is not a reliable method of securing the catheters. Hence a customized device has to be fabricated to prevent most of post radiation morbidity ensuring minimal radiation to unaffected surrounding tissues and maximizing radiation directly to specific sites.

Types of Radiation Prostheses

Carrier prostheses for holding radioactive sources or radiation beam cones (positioning stents), prostheses for displacing normal tissues, prostheses for protecting radiosensitive tissues (prosthetic shields), and prostheses for measuring radiation doses.(1-3)

CONCLUSION

This clinical report described constructing a customized orofacial brachytherapy carrier device that allowed the radiation oncologist and prosthodontist to enhance stability, retention and comfort of an orofacial-brachytherapy carrier. This report ensured minimal radiation to unaffected surrounding tissues and anatomic structures, while maximizing radiation directly to the specific sites.

REFERENCES

1. Pernot M, Aletti P, Carolus J, Marquis I, Hoffstetter S, Maaloul F, *et al.* Indications, techniques and results of postoperative brachytherapy in cancer of the oral cavity. *Radiotherapy and Oncology* 1995;35(3):186-92.

2. Arijji E, Hayashi N, Kimura Y, Uchida T, Hayashi K, Nakamura T. Customized mold brachytherapy for oral carcinomas through use of high-dose-rate remote afterloading apparatus. *Oral Surgery Oral Medicine Oral Pathology Oral Radiology and Endodontology* 1999;87(4):508-12.
3. Obinata K, Ohmori K, Tuchiya K, Nishioka T, Shirato H, Nakamura M. Clinical study of a spacer to help prevent osteoradionecrosis resulting from brachytherapy for tongue cancer. *Oral Surgery Oral Medicine Oral Pathology Oral Radiology and Endodontics* 2003;95:246-50.
4. Nag S, Cano ER, Demanes DJ, Puthawala AA, Vikram B. The American Brachytherapy Society recommendations for high-dose-rate brachytherapy for head-and-neck carcinoma. *International Journal of Radiation Oncology Biology Physics* 2001;50(5):1190-8.