

# Non Syndromic Anodontia: A Clinical Report of Two Cases

## Abstract

**Background:** Dental agenesis is the most common developmental anomaly in humans and is frequently associated with several other oral abnormalities. Some terms have been used in literature to describe congenital absence of teeth in primary dentition and/or in permanent dentition, such as Oligodontia, Anodontia and Hypodontia. Complete developmental absence of primary and/or permanent dentition is referred as true anodontia which is extremely limited to rare conditions. This clinical report presents two cases with complete agenesis of permanent dentition which are non-familial and non syndromic.

## Key Words

Anodontia; agenesis; oligodontia; non syndromic

Shruti Jalan<sup>1</sup>, Jogeswar Barman<sup>2</sup>

<sup>1</sup>Postgraduate Student, Department of Prosthodontics, Regional Dental College, Guwahati, Assam, India

<sup>2</sup>Reader, Department of Prosthodontics, Regional Dental College, Guwahati, Assam, India

## INTRODUCTION

Developmental absence of teeth often presents a significant clinical problem. It is classified according to the number of missing permanent teeth excluding the third molars.<sup>[1]</sup> True anodontia is a rare dental condition characterized by congenital absence of all primary and/or permanent teeth. Hypodontia is used to describe the absence of one or few teeth; oligodontia refers to agenesis of more than six teeth excluding the third molars.<sup>[2]</sup> Hypodontia and oligodontia can be categorized as partial anodontia, whereas oligodontia is also referred as severe or advance anodontia and selective tooth agenesis. The prevalence of dental agenesis shows a great variation, varying from 1.4% in Japanese to 11.3% in the Irish population<sup>[3]</sup> and 4.19% in Indian population.<sup>[4]</sup> Different frequency rate have been reported for hypodontia 1-10% and oligodontia 0.1-0.9% while true anodontia occurs very rarely, as only 17 cases have been reported over the last 50 years.<sup>[5]</sup> A meta-analysis made by Polder in 2004, showed that the dental agenesis is usually 1.37 times more frequent in females than in males.<sup>[4]</sup> The classification of tooth agenesis can be grouped as: syndromic and non-syndromic. Syndromic tooth agenesis which may occur in association with genetic syndromes, such as Ectodermal dysplasia, Incontinentia pigmenti, Down syndrome and Rieger syndrome.<sup>[5]</sup> The non-syndromic tooth agenesis with significant phenotypic variability has been classified as either:

sporadic and familial which can be inherited in an autosomal-dominant, autosomal-recessive, or X-linked mode.<sup>[6]</sup> Sporadic non-syndromic anodontia not involving associated abnormalities is extremely rare. Genetic and environmental factors may be of etiologic importance to this anomaly.<sup>[6]</sup> Brook (2009)<sup>[7]</sup> considered that complex interactions between various factors such as genetic, epigenetic and environmental factors causes dental anomalies during the process of dental development, which is multi-factorial, multilevel, multidimensional and progressive over time. In other words, the phenotype often reveals difference between affected individuals in the same family as a result of the multi-directional role of genetic, epigenetic and environmental factors in space and time. Several genes and molecular pathways are believed to be involved in tooth agenesis namely: Wnt/b, catenin/LEF1, MSX1, MSX2, PAX9, SHH, P63, Pitx2, Runx2/Cbfa1.<sup>[2]</sup> Rehabilitation of edentulous situation with total anodontia or severe oligodontia is extremely difficult. Congenital absence of multiple or all permanent teeth that results in developmental, functional and esthetic problems coupled with psychological complexities makes it more challenging, particularly when anterior teeth are involved.

## CLINICAL REPORT

Two young patients reported to the Department of Prosthodontics, Regional Dental College and Hospital, Guwahati with the chief complain of

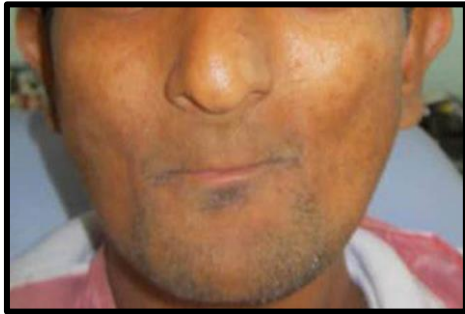

Fig. 1a

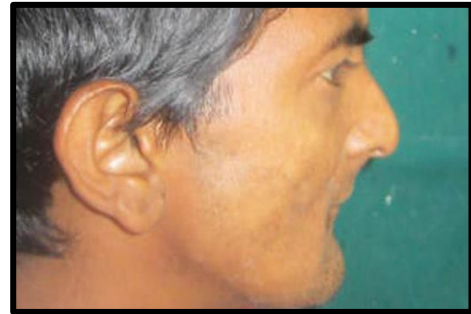

Fig. 1b

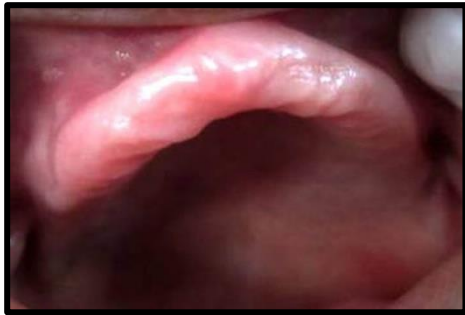

Fig. 2a

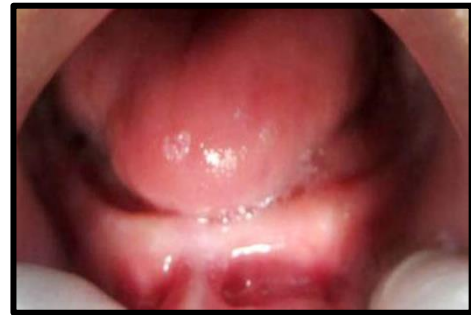

Fig. 2b

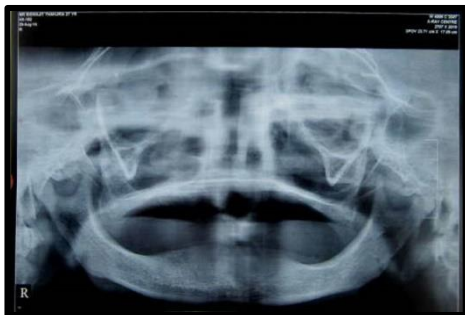

Fig. 3

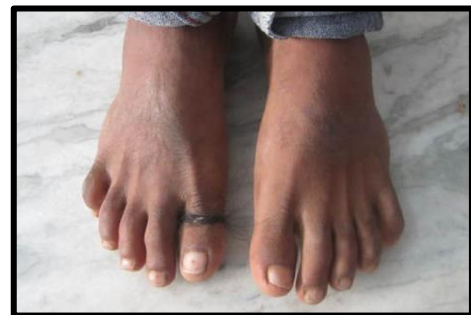

Fig. 4

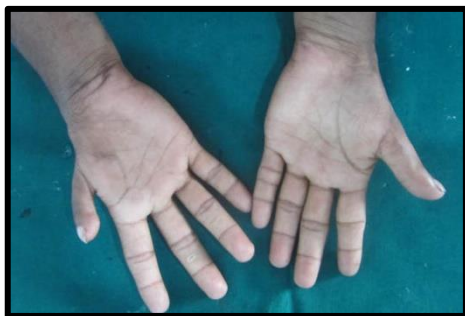

Fig. 5

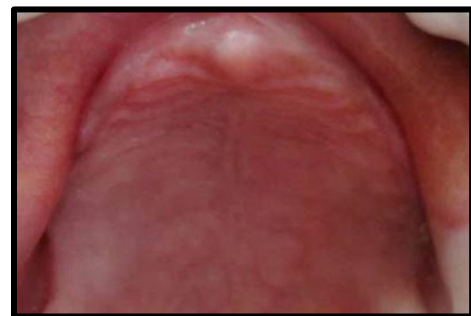

Fig. 6a

congenital missing of all permanent teeth and difficulty in eating food. The patient had a history of presence of primary dentition which then got decayed and shed off; the patients did not present any similar family history.

#### Case 1

A 26 year old male patient hails from a family of low socioeconomic status, moderately built and moderately nourished (Fig 1a & Fig. 1b) reported with no other history of systemic illness. Intraoral examination revealed edentulous maxillary and mandibular alveolar ridges, which are thin and

atrophic and micrognathic (Fig. 2). Anodontia as well as underdevelopment of ridges are also confirmed by panoramic radiograph (Fig 3). Extraoral examination revealed no signs and symptoms of ectodermal dysplasia such as nail dystrophy, hypotrichiosis (Fig. 4), absence of sebaceous glands (asteatosis), sweat glands, no depressed nasal bridge, protuberant lips, frontal bossing, sunken cheeks with prominent supraorbital ridges (Fig. 1 & Fig. 2) and palmoplantar dyskeratosis (Fig. 5) were found. Thus, the case was categorized under sporadic non syndromic

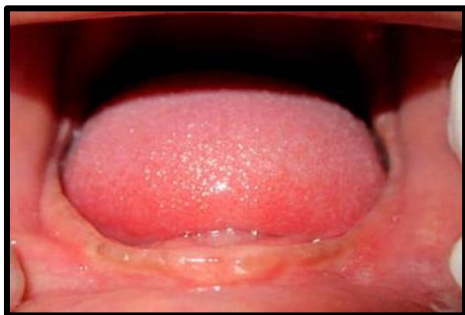

Fig. 6b

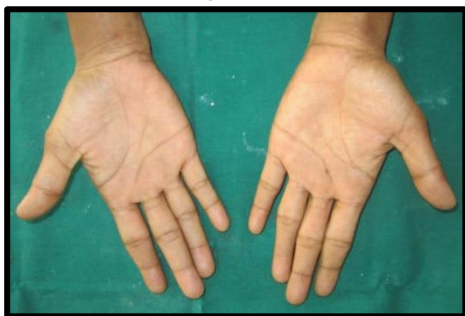


Fig. 8



Fig. 10

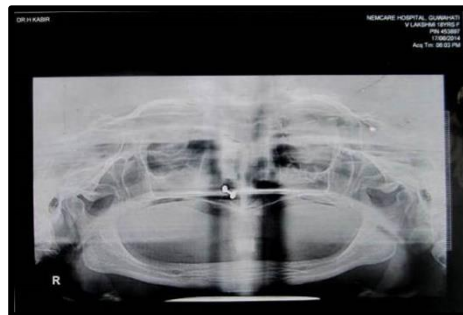

Fig. 7

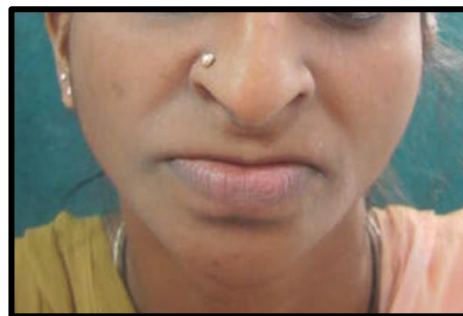

Fig. 9

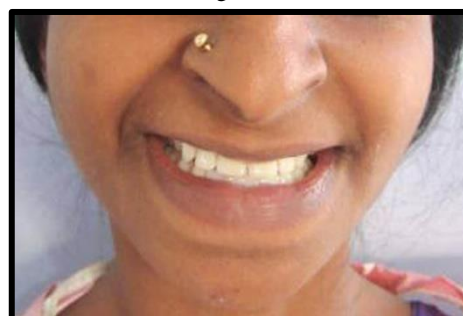

Fig. 11

anodontia.

### Case 2

An 18 year old female patient having similar built and nourishment also reported with anodontia and microgнатия (Fig 6a & Fig. 6b). After taking proper history, through examination and radiographic evaluation with panoramic view (Fig. 7), like the first case, this case was also categorized as sporadic non syndromic anodontia (Fig. 8 & Fig. 9).

### TREATMENT

Treatment options available for total anodontia patient are limited because of the lack of enough supporting oral structures. The following treatment modalities can be prescribed:<sup>[8]</sup>

1. Implant supported complete denture: This treatment measure will maintain alveolar bone and enhance the prognosis of prosthodontic treatment which is extremely important, especially in individuals with total anodontia. Lekholm gave age guidelines of 14 to 15 years of age for girls and a year later for boys. He also

recommends that an individual's growth curve be studied before any implant placement procedure is started.

2. Conventional complete dentures: Although complete dentures can provide an acceptable esthetic and functional result, underdevelopment of the edentulous alveolar ridges in individuals with anodontia can compromise denture retention and stability.

When there are no teeth available for complete denture support, vestibuloplasty and ridge augmentation may be considered as pre prosthetic management options that may enhance the prosthodontic management of anodontia. Treatment plan was discussed with both the patient and their attendants, in order to improve the appearance, mastication and speech. The scope and importance of the implant supported prosthesis was thoroughly discussed compared with the conventional complete denture prosthesis. However, considering the poor socioeconomic condition of both the patients, they were treated with complete balanced denture

prosthesis. Routine procedures were followed for construction of complete balanced denture prosthesis. The processed dentures were finished and polished, after the insertion of the dentures instructions were given to the patient and their attendants. The facial profile and appearance improved significantly with the complete denture prosthesis (Fig 10 & Fig. 11).

#### DISCUSSION

Both the cases presented in this clinical report had been diagnosed as non syndromic anodontia involving permanent dentition which is extremely rare. The exact etiology for the condition is still unknown. Perhaps the best family study of tooth agenesis was done by Grahnen<sup>[9]</sup> in 1956. He found that if either parent had one or more congenitally missing teeth, there was an increased chance that their children also would be affected. Genetic involvement was believed to be the root cause of Non sporadic anodontia.<sup>[6]</sup> But in the present two cases, the family history was negative. Several environmental factors such as viral infections, toxins and radio or chemotherapy<sup>[5]</sup> may also play important role in developmental absence of permanent teeth. The multidirectional involvement of genetic, epigenetic and environmental factors makes an accurate diagnosis of anodontia more complex and difficult. Through an evaluation to rule out multi factorial involvement demands multidisciplinary advanced approach. Schrubbe<sup>[10]</sup> found higher incidence of partial anodontia, caries and periodontitis in population of low socioeconomic status. Thus, from the patient's aspect, the socioeconomic condition and attitudinal and behavioural characteristics can obtrude the interdisciplinary approach for correct diagnosis and also prosthetic rehabilitation. The socioeconomic conditions of the present cases make them compromised and to be satisfied with the conventional complete denture prosthesis.

#### CONCLUSION

An understanding of the psychological status of anodontia patient is crucial to success of any prosthodontic treatment. The unaesthetic appearance, poor self-image, peer group pressure and discrimination in the school or job poses more psychological impact that can be minimized by early prosthetic management. Prosthetic intervention should be initiated with removable prosthesis and continued till full growth is attained. Treatment protocol includes periodic follow up for adjustment and remaking of the prosthesis during

rapid growth period. When full growth is achieved, treatment planning may includes implant supported fixed and/or removable prosthesis.

#### REFERENCES

1. Mahadevi B, Puranik RS, Shrinivas S. Oligodontia: A Case report and review of literature. *World J Dent* 2011;2:259-62.
2. Dali M, Singh R, Naulakha D. Idiopathic non syndromic tooth agenesis: A report of rare three. *J Interdiscip Dentistry* 2012;2:190-4.
3. Shimizu T, Maeda T. Prevalence and genetic basis of tooth agenesis. *Japanese Dental Science Review* 2009;45(1):52-9.
4. Bozga A, Stanciu RP, Mănuc D. A study of prevalence and distribution of tooth agenesis. *Journal of Medicine and Life* 2014;7(4):551-54.
5. Bajaj P, Sabharwal R, Joshi S. Non syndromic Oligodontia: A rare case report with review of literature. *DJAS* 2014;2(II):109-12.
6. Singer SL, Henry PJ, Lander ID. A Treatment planning classification for Oligodontia. *Int J Prosthodont* 2010;23:99-106.
7. Brook AH. Multilevel complex interactions between genetic, epigenetic and environmental factors in the aetiology of anomalies of dental development. *Arch Oral Biol* 2009;54:3-17.
8. Pigno M, Blackman BR, Cronin JR, Cavazos E. Prosthodontic management of ectodermal dysplasia: A review of the literature. *J Prosthet Dent* 1996;76(5):541-45.
9. Grahnen H. Hypodontia in the permanent dentition: Clinical and genetical investigation. *Odont Revy* 1956;7:15-9.
10. Schrubbe KF. A comparative study of oral/dental health status in an urban poor population over 100 years. (January 1, 2005). Dissertations (1962 - 2010) Access via Proquest Digital Dissertations Paper AAI3172504. <http://epublications.marquette.edu/dissertations/AAI3172504>