

## MINI REVIEW

# A Systematic Approach for Rehabilitation of Occlusion in Fixed Partial Denture

<sup>1</sup>Rita Zarina, <sup>2</sup>JL Jaini, <sup>3</sup>Rajan S Raj

## ABSTRACT

Long-term success of a restoration is dependent on maintenance of harmony between the various components of stomatognathic system. The goal of any restorative treatment is to establish posterior occlusal contacts that stabilize the occlusion and to provide anterior guidance which will provide predictable amount of disocclusion during protrusive and lateral excursions. The clinician should have fundamental knowledge about the components of stomatognathic system, to restore the occlusion for the optimal functioning of stomatognathic system. Evaluation, diagnosis, and treatment planning should be carried out to decide whether the existing occlusion should be changed or not. If a reorganized approach is needed, it requires correction of the existing occlusion and the generation of a new occlusal scheme. This is quite challenging. It is not possible to propose a single protocol to treat every case. However, this article proposes certain guidelines which could be modified depending on existing occlusal condition of the patient.

**Keywords:** Fixed partial denture, Interferences, Occlusion, Rehabilitation.

**How to cite this article:** Zarina R, Jaini JL, Raj RS. A Systematic Approach for Rehabilitation of Occlusion in Fixed Partial Denture. *Int J Prev Clin Dent Res* 2017;4(2):136-141.

**Source of support:** Nil

**Conflict of interest:** None

## INTRODUCTION

Symptoms of occlusal diseases are often hidden from the practitioner. This can be due to two reasons, either the practitioner is not trained to recognize them or unable to appreciate their significance and understand the consequences.<sup>1</sup> Long-term success of a restoration is dependent on maintenance of harmony between the various components of stomatognathic system. In order to achieve the skills required to provide sophisticated

treatment for complex occlusal problems, it may take years; however, the basic concepts should be understood by each practitioner.

## FACTORS INFLUENCING OCCLUSION IN FIXED PARTIAL DENTURE

### Role of Centric Relation and Centric Occlusion in Rehabilitation

The goal of any restorative treatment is to establish posterior occlusal contacts that stabilize the occlusion. In order to achieve this goal, we need to establish a stable, repeatable reference position to mount the casts on the articulator.<sup>2,3</sup> Centric relation provides this reference position, where we may establish the stable occlusion.

The bone of the glenoid fossa is thin in its most superior aspect, not suited for bearing stress. The slope of the eminence in the anterior aspect of the fossa is composed of thick cortical bone, i.e., capable to bear stress. Articular disk is biconcave and is devoid of nerves and blood vessels in the central area. The disk is attached to the condyle on its medial and lateral aspects and it should be interposed between the condyle and the articular eminence as function occurs. Irregular elliptical shape of condyle helps to distribute the stresses throughout the temporomandibular joint (TMJ) than that over a small area.

The condyle was sometimes forcefully manipulated into the rearmost, uppermost, and midmost position within the glenoid fossa, called the "RUM" position<sup>3-5</sup> using chin-point guidance. However, when the condyle is retruded, it may not be seated onto the central area of the articular disc. Instead it may be on the highly vascular and innervated retrodiscal tissues (the bilaminar zone) posterior to the disc. This can occur if the horizontal fibers of the temporomandibular ligament have been unduly traumatized. It is presently thought that rather than being a physiologic position, it is frequently an abnormal, forced position, which could create unnecessary strain in the TMJ. The disk will get displaced anteriorly and clicking of joint is observed as the patient opens and closes mouth. This results as the condyle recaptures the disk during functional movements. That is why it is stressed to generate the occlusion in a restoration to be made in harmony with the optimum condylar position, i.e., the centric relation.

<sup>1</sup>Professor and Head, <sup>2</sup>Reader, <sup>3</sup>Assistant Professor

<sup>1</sup>Department of Pedodontics and Preventive Dentistry Government Dental College, Kottayam, Kerala, India

<sup>2,3</sup>Department of Prosthodontics and Implantology, Amrita School of Dentistry, Kochi, Kerala, India

**Corresponding Author:** JL Jaini, Reader, Department of Prosthodontics and Implantology, Amrita School of Dentistry Kochi, Kerala, India, Phone: +919447461776, e-mail: drjainij@gmail.com

## Freedom in Centric Relation

Another method to develop a successful occlusion is to create no interferences from centric relation to centric occlusion and no interfering contacts in lateral eccentric movements throughout the functional occlusal range. This range of occlusion will produce what has been described as a long centric or freedom in centric relation.

## Mandibular Movements

It is essential to know the various mandibular movements that happen during normal functioning of stomatognathic system. Mandibular movements occur along three planes. The fixed partial denture and its occlusion are directly related to these movements. It is essential to capture the mandibular movements, so that the restorations can be fabricated in harmony with the mandibular movements, thereby enabling the restorations to function optimally.

## Determinants of Mandibular Movements

Posterior determinants are the two TMJs and the dentist has no control over them. They influence mandibular movements and thereby the movement of teeth. Recording and reproducing these movements form the basis for the use of articulators. Posterior teeth provide vertical stoppers for mandibular closure. They guide mandible to maximum intercuspal position. The anterior determinant – the anterior teeth – provides guidance to mandible in several ways. Anterior teeth guide mandible during protrusive and lateral excursions.<sup>1</sup> Canines are especially suited for this because it has the longest and strongest roots. Canines being placed away from the fulcrum together with proprioceptive threshold and concomitant reflexes reduce the load acting on them.<sup>6,7</sup> Neuromuscular system via proprioceptive impulses and reflex action will position the mandible such that it receives minimal stress. The objective of restorative dentistry is to produce teeth in harmony with TMJ, so that TMJ and teeth are subjected to minimum stress. It should impart minimum stresses on neuromuscular system to produce mandibular movement.<sup>1</sup>

## Interferences

When teeth are not in harmony with the TMJ and mandibular movements, interferences are said to exist. They are undesirable occlusal contacts that may produce mandibular deviation during closure to maximum intercuspal position or may hinder smooth passage from and to maximal intercuspal position. They are of four types.<sup>1</sup>

*Centric interferences:* These are premature contacts that occur when the mandible closes with the condyles in optimum condylar position. The mandible may get deflected to anterior, posterior, and/or lateral direction,<sup>8</sup>

usually occur between maxillary mesial cuspal inclines and mandibular distal inclines and mandible is deflected anteriorly.<sup>1</sup>

Working side is the side to which mandible is moved. When interferences occur on that side which is heavy enough to disocclude the anterior teeth, it is an “interference”.<sup>9</sup> Usually occur between maxillary lingual facing inclines and mandibular buccal facing inclines.<sup>1</sup>

Nonworking side interferences occur on nonworking side or from the side from which the mandible is moved.<sup>10,11</sup> They are highly destructive in nature to the stomatognathic system. They occur between maxillary buccal facing inclines and mandibular lingual facing inclines.<sup>1</sup>

Protrusive interferences are premature contacts occurring between the mesial aspect of mandibular posterior teeth and distal aspect of maxillary posterior teeth. They are potentially destructive and interfere with patient's ability to incise food.<sup>1</sup>

## NORMAL VS PATHOLOGICAL OCCLUSION

In only slightly more than 10% of the population, is there complete harmony between the teeth and the TMJ.<sup>12</sup> In a majority of the population, the position of maximum intercuspal position causes the mandible to be deflected away from its optimum position. In the absence of symptoms, this can be considered physiologic or normal. Therefore, in a normal occlusion, there will be a reflex function of the neuromuscular system, producing mandibular movements that avoid premature contacts. The result will be hypertonicity of muscles and trauma to TMJ. This will be well within most people's physiologic capacity to adapt and will not cause discomfort.<sup>1</sup> However, the patient's ability to adapt may be influenced by the effects of psychic stress and emotional tensions on the central nervous system.<sup>13</sup> This may lower the threshold to adapt, parafunctional activity may develop, these will make a normal occlusion pathologic. Simple muscle hypertonicity may give way to muscle fatigue and spasm, chronic head ache, muscle tenderness, and finally leads to TMJ dysfunction. Clinicians have to trace out these interferences and its consequences during examination. When we treat a patient with acute symptoms and when the pathologic occlusion is relieved, changes should come in occlusion so that pathologic signs will not recur.<sup>1</sup> It is equally important that when we treat and place a bridge on a patient without symptoms, we should not produce iatrogenic pathologic occlusion.

## ORGANIZATION OF OCCLUSION/ OCCLUSAL SCHEMES

There are three accepted concepts that describe the manner in which teeth should contact in the various functional and excursive positions of the mandible.

## **Bilateral Balanced Occlusion**

It is largely a prosthodontic concept which dictates that a maximum number of teeth should contact in all excursive positions of the mandible. It is used especially in complete denture construction. Subsequently, the concept was applied to natural teeth in complete occlusal rehabilitation. An attempt was made to reduce the load on individual teeth by sharing the stress among as many teeth as possible.<sup>14</sup>

## **Unilateral Balanced Occlusion**

Commonly known as group function, it is a widely accepted method of tooth arrangement in restorative procedures. It was introduced by Schuyler. According to this concept, all the teeth on the working side should be in contact during a lateral excursion and teeth on the nonworking side are contoured to be free of any contact. The group function of the teeth on the working side distributes the occlusal load. The absence of contact on the nonworking side prevents those teeth from being subjected to the destructive, obliquely directed forces found in nonworking interferences. It also saves the centric holding cusps from excessive wear. The advantage is maintenance of occlusion.<sup>1</sup>

## **Mutually Protected Occlusion**

It is also known as canine-protected occlusion or organic occlusion. According to this, the overlap of anterior teeth prevents the posteriors from making any contact on either the working or nonworking side during mandibular excursions. This separation from occlusion is termed disocclusion. Hence, the anteriors bear the entire load and the posteriors are disoccluded in any excursive positions of the mandible. The desired result is absence of frictional wear.<sup>15,16</sup>

## **GENERATION OF OCCLUSION FOR FIXED PARTIAL DENTURE**

### **Analysis of Occlusion**

Any rehabilitation starts with analysis of existing occlusion. Patient should be manipulated to his centric relation, and occlusion should be analyzed. Whether centric relation is coinciding with maximum intercuspal position or not is to be evaluated. Clinician should note whether freedom in centric occlusion is existing or not. Existing anterior guidance should be evaluated, to find out the anterior guidance. Those teeth which guide the mandible in protrusive and lateral excursive movements should be noted. Using different colored articulating papers, the interferences in centric and protrusive relation should be

noted. Working and nonworking side interferences also should be evaluated.

### **Recording the Existing Occlusion**

These rely on marking the static and dynamic occlusal contacts between the teeth and then describing those contacts in writing by diagram or photograph. Articulating papers, floss or shimstock, and T-scan can be used to determine the occlusal contacts. A three-dimensional registration is also desirable. The study models will be articulated to the existing occlusion by employing a face bow transfer and semiadjustable articulator.<sup>17,18</sup>

### **Diagnosis and Treatment Planning**

Based on history, examination, mounted diagnostic casts, and radiographs, diagnosis and treatment planning will be done. In order to proceed with rehabilitation, clinician should choose one of the approaches described below.

### **Confirmative Approach**

The confirmative approach is defined as the provision of restorations in harmony with the existing jaw relationships.<sup>19</sup> In practice, this means that the occlusion of the new restoration is provided in such a way that the occlusal contacts of the other teeth remain unaltered.<sup>20</sup> The confirmative approach is favored not because of its safety but its less probability to create problems to teeth, periodontium, muscles, TMJs, patient, and the dentist. It could be because the centric relation and maximal intercuspal position are coinciding. At times centric relation and maximal intercuspal position may not be coinciding, yet if we remove an interference, the new occlusion still would not result in an ideal occlusion. This generated less than ideal occlusion may be less harmonious than, one that was existing. The patient will tolerate this adjusted occlusion less well.<sup>21</sup> If this approach is opted then rehabilitation is executed in the traditional way, in harmony with existing occlusion. In order to recreate the occlusion functionally generated pathway will serve as a good technique.

### **Reorganized Approach**

At times, the clinician will realize that the confirmative approach is not appropriate for the longevity of restoration and to maintain the health of stomatognathic system. It could be in situations like,

- An increase in vertical height is mandatory.
- A tooth or teeth are out of occlusion.
- A significant change in appearance is wanted.
- History of occlusally related failure or fracture of existing restorations.
- Recurrence of temporomandibular disorder that has relapsed after a period of successful splint therapy.<sup>22</sup>

It is not possible to propose a single protocol to treat every case. However, the following guidelines will serve as a generally applicable protocol which should be modified depending on existing occlusal condition of the patient.

- Evaluation of occlusion will be conducted as described above. Maximal intercuspal position if not happening in centric relation, the centric relation must be found out. The accurate assessment of centric relation may be made more difficult by the length of time during which the patient functions with a habitual closure pattern and thereby guarding the damaging deflective contacts.
- It is often necessary to de-program the musculature for some period of time before recording the centric relation. Multiple appliances are available like Lucia jig, stabilization splints, kois deprogrammer, etc. The practitioner should choose one that will match for the patient's condition.
- Once the habitual pattern of closure is deprogrammed, a face bow transfer will be done. Using an appropriate technique, centric relation will be recorded. Maxillary and mandibular casts will be mounted in this relation on the semiadjustable articulator. An estimate of the patient's condylar angle also will be checked. This can be done on the articulator as well as on the mouth by guiding the mandible to protrusive relation and recording it. There should be two sets of cast mounted in centric relation. One to set as a reference occlusion and other one to proceed as diagnostic wax up.
- Depending on the interferences and discrepancies that exist in the mouth, an assessment of mouth preparation will be done. A mock equilibration will be performed on one of the mounted models until multiple ideal contacts between opposing teeth occur in centric relation. It is performed at times to gain space for generating a proper occlusion and occlusal scheme in this existing centric relation.
- Clinician by doing this judges whether these alterations are possible or not, inside the mouth. At times, it will not be possible to achieve an ideal occlusion without major alterations of teeth. This may indicate a need for considering provisional restorations of some type or orthodontic adjustment and even extraction.
- Following these, a diagnostic wax up will be made. If occlusal scheme is to be modified, diagnostic wax up provides positive information on the occlusal scheme that can be generated. It serves as an opportunity to visualize the end point of an occlusion. The greatest difficulty in designing the occlusion in a diagnostic wax up is to generate an occlusal plane. This can be assisted by the use of a flag on the articulator or a Broadrick occlusal plane analyzer.
- The sequence of mock equilibrium should be recorded and duplicated in mouth exactly in the same manner as it is conducted on the mounted models.<sup>22</sup>
- Following the equilibration inside the mouth, an index of anterior teeth is made using bite registration paste in centric relation. Using this, the mandible will be reoriented into centric relation even after posterior contacts are lost. Teeth preparation for posterior teeth will be done. Using the anterior index, mandible will be brought to centric relation position. Bite registration of posterior teeth will be done.
- Anterior teeth will be prepared and relation of prepared teeth in centric relation will be recorded with the help of posterior index (Fig. 1).
- Impressions will be made. Working cast and die preparations will be made. A face bow transfer is made and models are articulated. Lower model will be mounted with the help of anterior and posterior indexes.
- Putty indexes of diagnostic wax up (Fig. 2) is made and used for fabrication of provisional restorations (Fig. 3). Following cementation of provisional restorations, clinician should be able to generate the same occlusion, i.e., existing in diagnostic wax up.

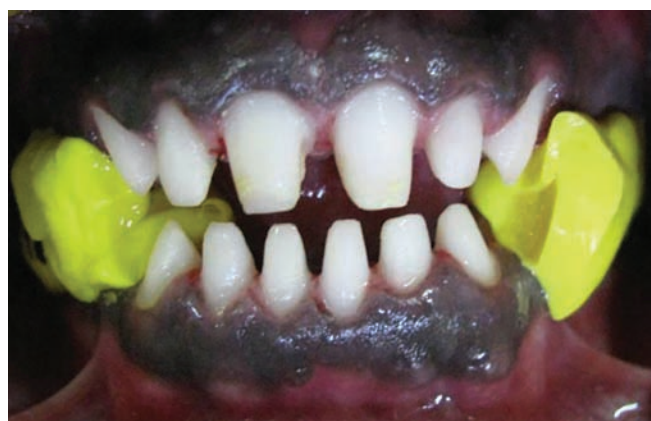

Fig. 1: Evaluation of anterior teeth preparation with the help of posterior index

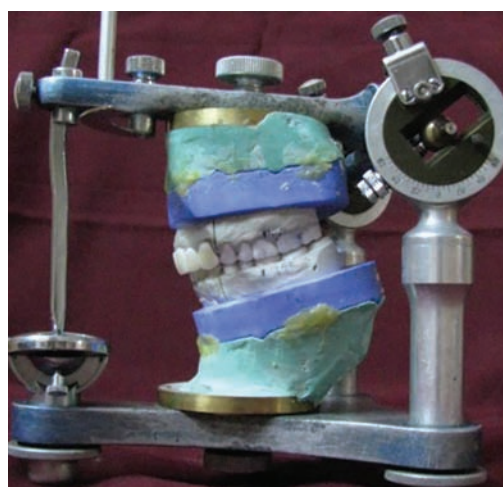

Fig. 2: Diagnostic wax-up



Fig. 3: Putty indexes fabricated for provisional restoration



Fig. 4: Mounted casts of cemented provisional restorations

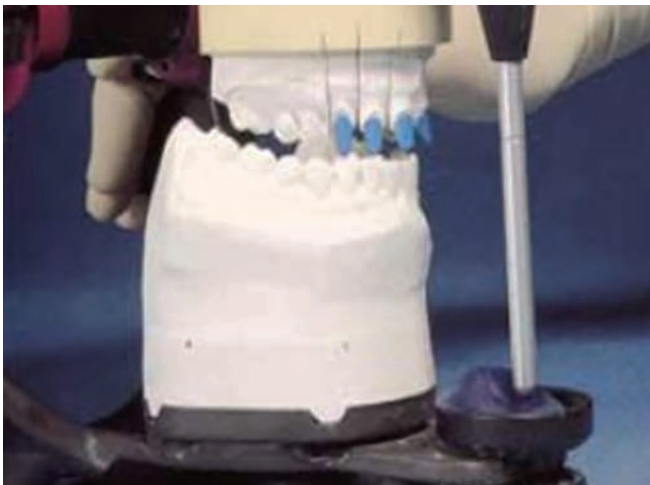


Fig. 5: Mounted cast of prepared tooth

- The provisionals will be evaluated for a period of time to assess the compliance of the generated occlusion. If modifications are needed, changes will be made. When everything is fine for the patient, impressions of cemented provisional restorations will be made. A face bow transfer and mounting of the maxillary cast will be done. Centric relation will be recorded and mandibular cast will be mounted on the articulator. Following this, a customized incisal table will be made on the articulator. This will act as a reference for generating occlusion as like with cemented provisional restorations in mouth.(Figs 4 and 5).<sup>22</sup>
- This incisal guidance will be placed on the articulator with mounted models of prepared teeth. This will help to set the protrusive and lateral angles exactly in the same way as like with provisional mounting. This will enable to reproduce the same amount of disocclusion during protrusive and lateral excursions, during fabrication of permanent porcelain restorations.
- The restorations can be evaluated inside mouth to confirm the planned occlusion before glazing of porcelain.

## CONCLUSION

Generation of an occlusal scheme that will function in harmony with patient's stomatognathic system can be created in a predictable manner. It requires meticulous planning and execution. It is more dependent on the planning than the skill or knowledge of practitioner, even though they contribute significantly.

## REFERENCES

1. Shillingburg HT, Hobo S, Whitsett LD, Jacobi R, Brackett, SE. Fundamentals of occlusion. In: Bateman LA, editor. Fundamentals of fixed prosthodontics. 3rd ed. Chicago: Quintessence Publishing Co, Inc; 1997. p. 11-24.
2. McCollum BB, Stuart CE. Gnathology – a research report. South Pasadena, CA: Scientific Press; 1955. p. 91-123.
3. Lucia VO. Modern gnathological concepts. St Louis, MO: CV Mosby Co; 1961. p. 15-22.
4. Dawson PE. Evaluation, diagnosis, and treatment of occlusal problems. St Louis, MO: CV Mosby Co; 1974. p. 293.
5. Kornfeld M. Mouth rehabilitation. St Louis, MO: CV Mosby Co; 1967. p. 34.
6. Manly RS, Pfaffmann C, Lathrop DD, Kayser J. Oral sensory thresholds of persons with natural and artificial dentitions. J Dent Res 1952 Jun;31(3):305-312.
7. Williamson EH, Lundquist DO. Anterior guidance. Its effect on electromyographic activity of the temporal and masseter muscles. J Prosthet Dent 1983 Jun;49(6):816-823.
8. Dawson PE. Temporomandibular joint pain-dysfunction problems can be solved. J Prosthet Dent 1973 Jan;29(1): 100-112.
9. Dawson PE. Evaluation, diagnosis, and treatment of occlusal problems. St Louis, MO: CV Mosby Co; 1961. p. 299.
10. Ramfjord SP. Dysfunctional temporomandibular joint and muscle pain. J Prosthet Dent 1961;11(2):353-374.
11. Stallard H, Stuart CE. Eliminating tooth guidance in natural dentitions. J Prosthet Dent 1961;11:474-479.
12. Posselt U. Studies in the mobility of human mandible. Acta Odontol Scand 1952;10 (Suppl 10):1-109.
13. Ramfjord SP, Ash MM. Occlusion. 2nd ed. Philadelphia: WB Saunders Co; 1971. p. 104.

14. Schuyler CH. Fundamental principles in the correction of occlusal disharmony, natural and artificial. *J Am Dent Assoc* 1935 Jul;22(7):1193-1202.
15. D'Amico A. Functional occlusion of natural teeth of man. *J Prosthet Dent* 1961;11(5):899-915.
16. Stuart CE. Good occlusion for natural teeth. *J Prosthet Dent* 1964;14:716-724.
17. Davis S, Gray RMJ. What is occlusion? *Br Dent J* 2001 Sep 8;191(5):235-245.
18. Davis S, Gray RMJ. What is occlusion? *Br Dent J* 2001 Sep 22;191(6):291-302.
19. Celenza FV, Litvak H. Occlusal management in conservative dentistry. *J Prosthet Dent* 1976;36:164-170.
20. Foster LV. Clinical aspects of occlusion: 1. Occlusal terminology and confirmative approach. *Dent Update* 1992 Oct;19(8):345-348.
21. Davis S, Gray RMJ, Smith PW. Good occlusal practices in simple restorative dentistry. *Br Dent J* 2001 Oct;191(7):365-385.
22. Davis S, Gray RMJ, Whitehead SA. Good occlusal practices in advanced restorative dentistry. *Br Dent J* 2001 Oct 27;191(8):421-434.