

CASE REPORT

Revisiting the Simple, Cost-effective, Noninvasive and Esthetically Acceptable Auricular Prosthesis

¹Abhay Kant, ²Sudhakara G Bhat, ³Shivamurthy Shadakshari, ⁴Sanjayagouda B Patil, ⁵HS Kiran Kumar
⁶Blessy Joseph, ⁷Nivea T Francis, ⁸Kirti Agrawal

ABSTRACT

Aim: The aim of this study is to describe a simple, cost-effective, and noninvasive method of fabricating an esthetically acceptable hair band-retained polymethylmethacrylate auricular prosthesis.

Background: Auricular tissue defects may be congenital or acquired. Acquired auricular defects may be because of trauma, surgery, and pathology. Orofacial defects including auricular defects not only create esthetic problems but also has psychological impact on the patient. A surgical reconstruction involving a large defect is generally difficult and often fails to provide satisfying results. Rehabilitation with a simple prosthesis improves esthetics and self-esteem of the patients, thereby better social integration that makes them feel safe and happy.

Case report: A 23-year-old girl reported to the Department of Prosthodontics, Sri Hasanamba Dental College & Hospital with an auricular defect due to trauma. On examination, a large part of left ear was missing. Impressions of both defective and normal ears were made using hydrocolloid impression material. Wax pattern was sculpted and was tried on the left auricular defect. Sculpted wax pattern was flaked and processed with intrinsically stained polymethylmethacrylate heat cure acrylic resin. After aligning in proper position, the prosthesis was attached to the hair band which provided the necessary retention to the prosthesis. Prosthesis was esthetically acceptable and instructions regarding maintenance were given to the patient.

Conclusion: The hair band-attached auricular prosthesis was esthetically acceptable, economically cost-effective, convenient, and easy to repair. Auricular prosthesis improved the appearance, self-confidence, and social acceptance of the patient.

Clinical significance: Metallic hair band-retained auricular prosthesis is a good option for patients who are not willing to undergo surgery or cannot bear financial burden of implants.

Keywords: Auricular prosthesis, Hair band retention, Polymethylmethacrylate, Prosthetic rehabilitation.

How to cite this article: Kant A, Bhat SG, Shadakshari S, Patil SB, Kumar HSK, Joseph B, Francis NT, Agrawal K. Revisiting the Simple, Cost-effective, Noninvasive and Esthetically Acceptable Auricular Prosthesis. *Int J Prev Clin Dent Res* 2017;4(2):148-152.

Source of support: Nil

Conflict of interest: None

BACKGROUND

Auricular defects can be rehabilitated in two ways: By surgical intervention or by prosthetic rehabilitation. Because of a large defect, surgical intervention alone cannot obtain required results. It has to be associated with the prosthetic rehabilitation after executing surgical procedure. In such situations, surgical intervention is not the preferred method.¹ Prosthetic rehabilitation ensures predictable outcome as well as being a noninvasive method. Predictable results help to reduce the psychological trauma. The fabrication of ear prosthesis is considered by many prosthodontists to be one of the more difficult replacements in maxillofacial reconstruction. The severe undercuts and pronounced convolutions of the ear surface present a challenge in simulating a natural proportioned ear.²

Pare (1517–1590) advocated the use of a prosthesis to replace the missing ear and this extraoral prosthetic device was meant to be held in place by a metal band that went over head.³

Vianna⁴ used acrylic resin with an intrinsic pigment for prosthesis. Retention was supplied by the temple pieces of glasses, a slight vertical support in the auditory canal, and a sheet of elastic rubber behind the head.

In 1967, Arturo Santiago used a vinyl resin for preparation of prosthesis. It was held in place with double-faced tape.²

In 1969, Brown prepared ear prosthesis with three-piece die technique with pure silicon, and retention was achieved by skin adhesive.²

Parel used medially tensioned eye glasses and temple piece, engaging various convolution of the remaining tissue, and external auditory canal for retention of prosthesis.²

^{1,6,7}Postgraduate Student, ²Professor and Head, ^{3,4}Professor
⁵Senior Lecturer, ⁸Consultant

¹⁻⁷Department of Prosthodontics, Crown and Bridge including Implantology, Sri Hasanamba Dental College & Hospital Hassan, Karnataka, India

⁸Department of Orthodontist, Agarwal Dental Clinic, Auraiya Uttar Pradesh, India

Corresponding Author: Abhay Kant, Postgraduate Student Department of Prosthodontics, Crown and Bridge including Implantology, Sri Hasanamba Dental College & Hospital Hassan, Karnataka, India, Phone: +917406438348, e-mail: abhaykant289@gmail.com

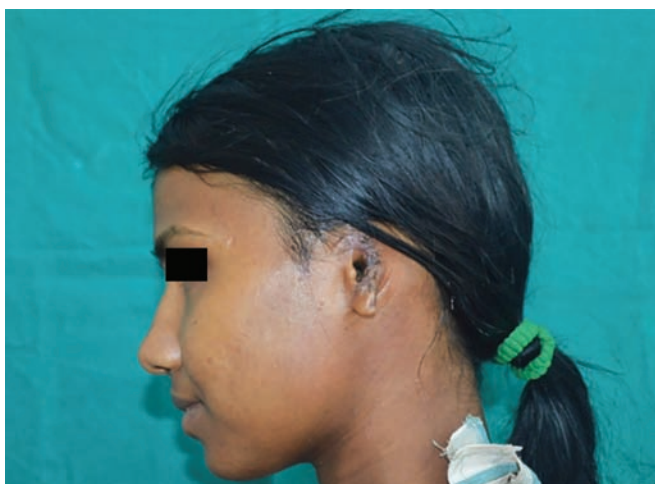

Fig. 1: Defective left ear

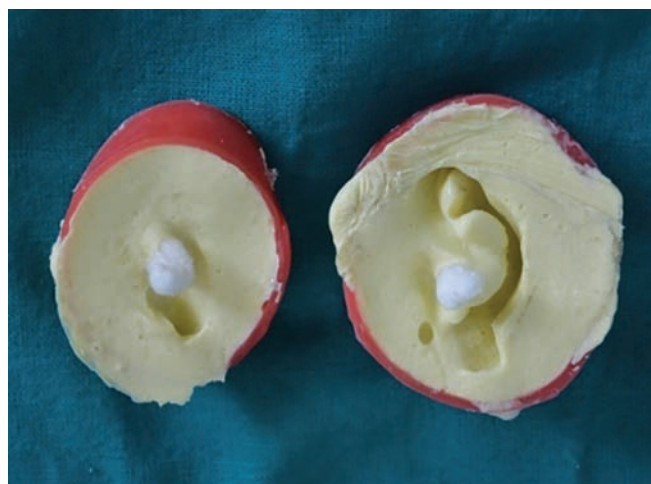

Fig. 2: Impressions of both ears

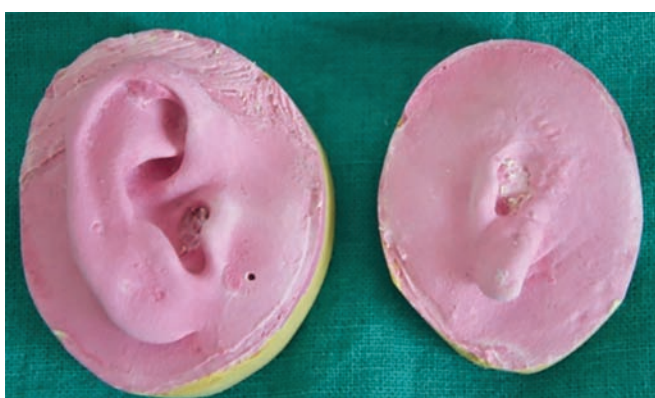

Fig. 3: Stone models for both ears

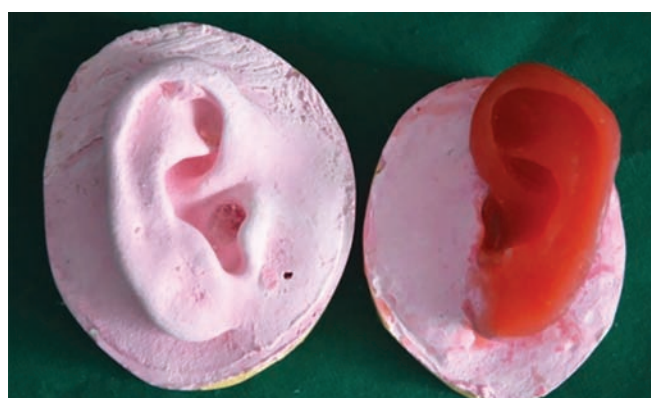


Fig. 4: Sculpted wax pattern

Requirements of an ideal auricular prosthesis are esthetics, retention, stability along with correct alignment and positioning, biocompatibility, and longevity.⁵ This case report describes the procedure of fabrication of hair band-retained auricular prosthesis to fulfill the mentioned requirements.

CASE REPORT

A 23-year-old girl reported to the Department of Prosthodontics, Sri Hasanamba Dental College & Hospital, Hassan, Karnataka, India, with complaint of loss of left ear due to trauma. On examination, there was a large defect with loss of helix, antihelix, scaphoid fossa, and triangular fossa. Only tragus and part of lobule was remaining with a normal external auditory meatus. Skin over the defect was scarred with suture markings (Fig. 1). An intrinsically stained polymethylmethacrylate prosthesis retained by hair band was to be fabricated to rehabilitate the appearance and psychology of the patient.

Defected area was thoroughly cleaned using povidone-iodine solution and a layer of petroleum jelly was applied over the scarred skin and surrounding tissue.

A small piece of cotton was rolled into a small ball that fit snugly into the external auditory meatus and was inserted to control the flow of impression material in the ear. Defected area and contralateral normal ear were boxed with modeling wax individually. Alginate was mixed with cold water to increase working time. Mixed alginate had thin consistency and was poured into the boxes. After the material was set, impressions were retrieved (Fig. 2). Auricular impressions were first poured using a layer of die stone to get fine surface details and surface hardness. Before the die stone was set, dental stone was poured to get sufficient thickness of base of the cast (Fig. 3). Wax pattern on the defect cast was sculpted using the right side ear as a guide. To fabricate identical ear wax pattern, meticulous care was taken for height, width, and uniform thickness (Fig. 4). Scale and divider were used to get proper dimensions and shape. As the skin texture is not glossy, to simulate and create the tissue surface texture of the ear, flaming of the wax work and damping with a piece of wet gauze was done.⁶

Carved wax pattern was tried and it was held in position. Frontal and lateral views were checked to verify symmetry with the other side and changes were done

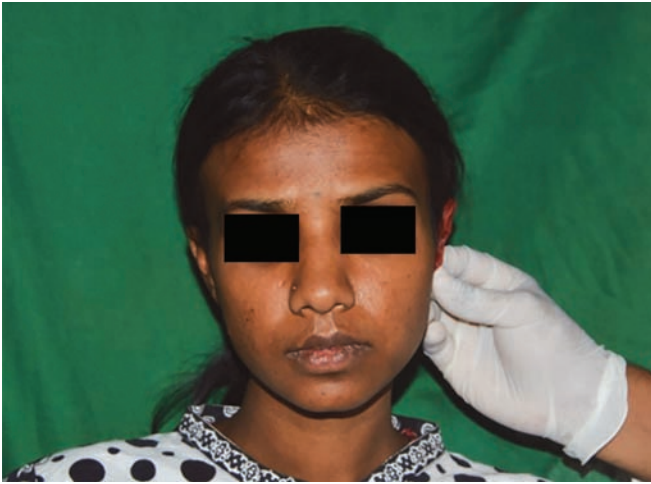

Fig. 5: Try-in of sculpted auricular wax pattern

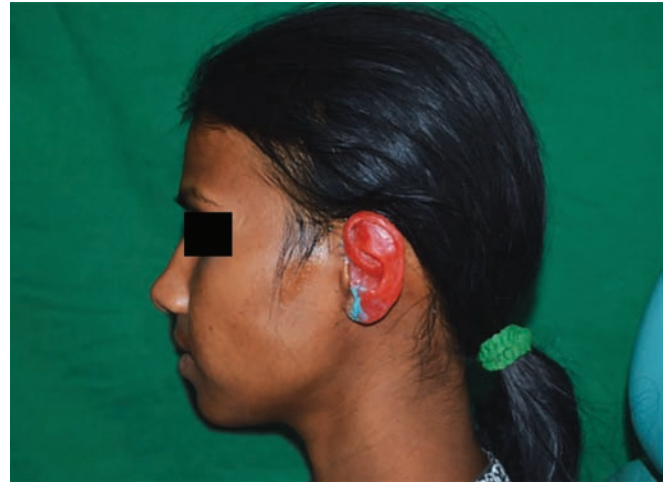

Fig. 6: Relined impression of the wax pattern

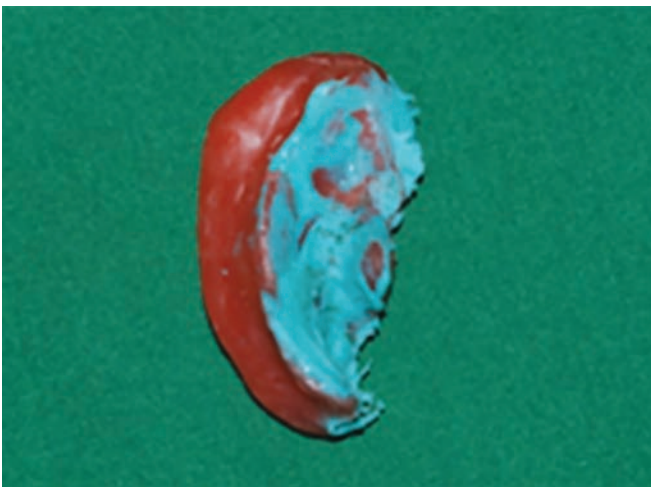

Fig. 7: Relined auricular wax pattern

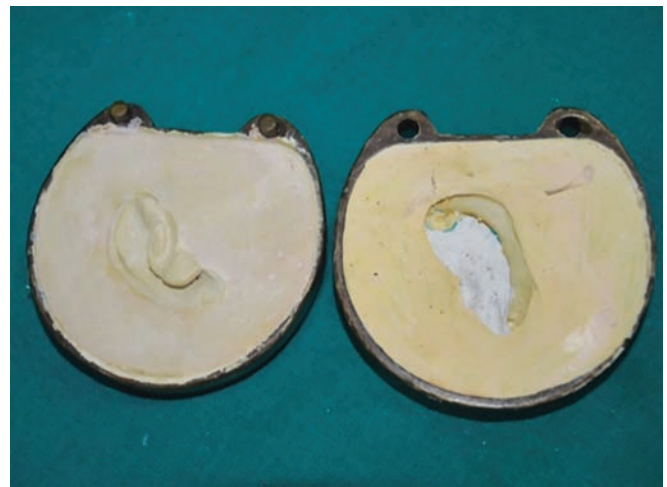

Fig. 8: Dewaxing of the wax pattern

accordingly (Fig. 5). Patient and patient's family member opinions were taken during auricular wax try-in procedure regarding any modification. After final correction, to get proper adaptation to the tissue, reline impression was made with light body polyvinylsiloxane impression material after applying the tray adhesive in the fitting surface of the wax pattern (Figs 6 and 7).

Carved wax pattern was flaked using three-pour technique. First layer of plaster of paris was poured to the tissue level of the carved wax pattern and separating medium was applied and second layer of dental stone was poured to the highest level of the prosthesis, but care was taken to prevent the flow of dental stone into the depressions of carved wax pattern. Then separating medium was applied and counter-flasking was done. This was done for easy application of laminar glaze⁷ technique and to facilitate easy retrieval of the prosthesis. Once dental stone was set, dewaxing was done (Fig. 8) and separating medium was applied.

One full-day appointment was planned for auricular prosthesis shade selection. Trial and error method⁷ was

used to get proper shade. Pink, translucent, veined acrylic along with brown, red, yellow stains were used to get proper shade. Base plate and areca nut powder were added to get life-like appearance. Laminate glazes were applied in the counter-flask and base color was packed in the lower portion of the flask and heat cure polymerization was done.

After polymerization, prosthesis was retrieved, trimmed, cleaned, and buffed lightly with pumice. Sandpapering was avoided to maintain texture of the prosthesis. Prosthesis was tried on the defect side of face. A barrier of cellophane layer was placed to prevent contact of the intrinsically stained autopolymerizing polymethylmethacrylate to the hair and skin (Fig. 9). Frontal and lateral views were checked for symmetry with other side of face. After aligning the prosthesis in correct orientation, it was attached to hair band by intrinsically stained self-cure resin (Figs 10 and 11). Prosthesis was finished and delivered to patient. Instructions regarding the maintenance of the prosthesis were given to patient.

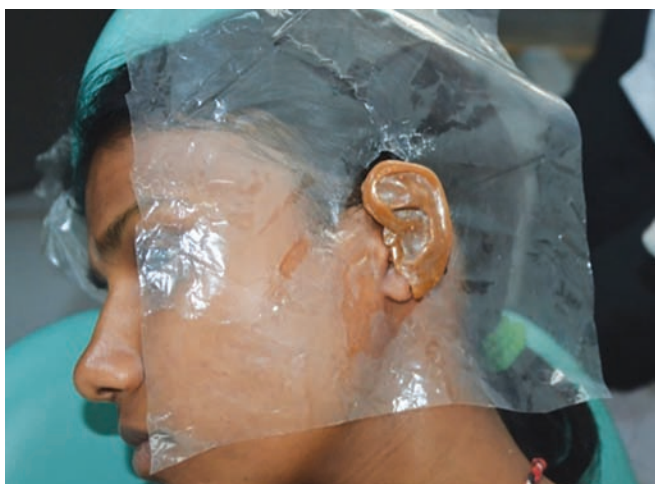

Fig. 9: Attaching finished prosthesis with hair band

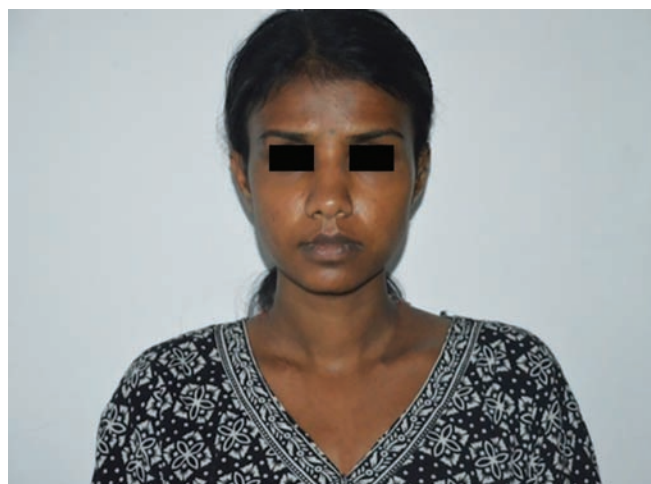

Fig. 10: Frontal view of final prosthesis in place

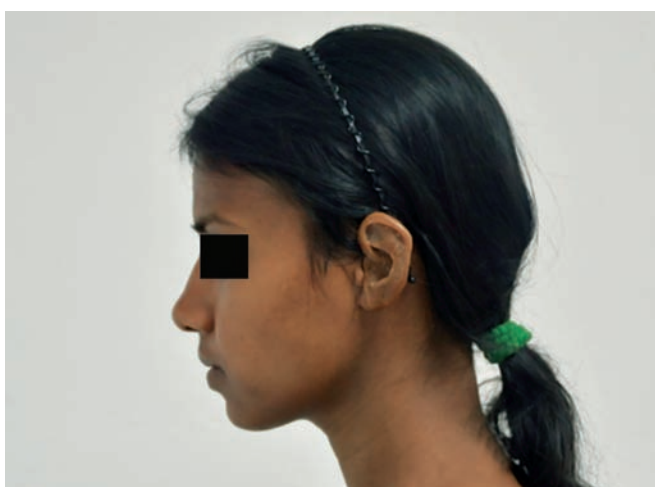

Fig. 11: Lateral view of final prosthesis in place

DISCUSSION

Leading life with deformity in an esthetic area causes psychological exertion. It also affects patient's emotional, mental, and social life. That is why prosthetic rehabilitation of missing facial part, such as ear is a task expecting apparent skill for fine detailing in prosthesis.

The psychologically unstable patient was not willing to undergo repeated reconstructive surgical procedures. Financially also, patient was unable to afford the implant-supported prosthesis. Small mobile lobule left behind and irregular scarred skin surface were negative points toward the use of adhesive. Patient preferred to use hair band as a retentive aid instead of spectacles. A metal hair band was selected which had more flexible properties and some retentive feature to be fixed to intrinsically stained self-cure acrylic resin.

Reline impression with polyvinylsiloxane impression material after try-in improved the adaptation of the auricular prosthesis to the defective tissue. This in turn reduced discomfort to the patient and improved esthetics of the prosthesis.

Silicone materials have low tear strength in thin sections and low color stability, which are difficult to maintain and repair. Thus, polymethylmethacrylate was preferred for auricular prosthesis over silicone material. Polymethylmethacrylate is easy to handle, easy to repair, cost-effective, and easy to maintain. As economical treatment option, acrylic resin is the material of choice for fabrication of auricular prosthesis.⁸

According to studies by Leow et al,⁹ coloring pigments are known to undergo discoloration after sometime due to exposure to ultraviolet light, elevated temperatures, and sweat. In the present case, dry color pigments were intrinsically used for the ear prosthesis. Intrinsic coloration is superior than extrinsic coloration as it makes the prosthesis less susceptible to environmental changes and provides better handling.¹⁰ Patient was informed regarding the discoloration of the prosthesis and was advised for refabrication of the prosthesis when required.

Finally, the prosthesis was well adapted to the skin, simulating the natural ear with excellent color matching.

CONCLUSION

The hair band-retained polymethylmethacrylate prosthesis was esthetically well accepted, cost-effective, and easy to use and fabricate. It is a convenient choice for patients who cannot bear financial load or are not willing to undergo surgery.

REFERENCES

1. Goiato MC, Pesqueira AA, Ramos da Silva C, Gennari Filho H, Micheline Dos Santos D. Patient satisfaction with maxillofacial prosthesis. Literature review. *J Plast Reconstr Aesthet Surg* 2009 Feb;62(2):175-180.
2. Shah DN, Chauhan CJ. Auricular prosthesis – the overlooked skill in prosthodontics. *J Ahmedabad Dent Coll Hosp* 2010 Mar-Aug;1(1):37-40.
3. Balbulian AH. Maxillofacial prosthetic: evolution and practical application in patient rehabilitation. *J Prosthet Dent* 1965 May-Jun;15(3):554-569.

4. Vianna CB. Nontypical prosthesis of ear. *J Prosthet Dent* 1960 Sep-Oct;10(5):987-988.
5. Minati C, Shanmuganathan N, Jain BS, Padmanabhan TV. Hair band retained prosthetic reconstruction of bilaterally missing ears: a case of atresia of external auditory canals and pinna. *J Prosthodont Res* 2014 Jan;58(1):62-67.
6. Gupta A, Gupta SK. Adhesive retained silicone ear prosthesis – a boon for anotia. *IOSR-JDMS* 2015 Mar;14(3):56-62.
7. Seelaus, R.; Troppmann, RJ. Facial prosthesis fabrication: coloration techniques. In: Taylor TD, editor. *Clinical maxillofacial prosthetics*. China. Quintessence Publishing Co, Inc.; 2000. p. 245-264.
8. Khindria SK, Bansal S, Kansal M. Maxillofacial prosthetic materials. *J Indian Prosthodont Soc* 2009 Jun;9(1):2-5.
9. Leow ME, Ow RK, Valiyaveetil S, Lee MH, Pho RW. Colour-fast pigments in silicone hand and maxillofacial prostheses. *Prosthet Orthot Int* 2002 Aug;26(2):124-134.
10. Arora A, Pasam N, Gilra S, Arora PC. Prosthetic rehabilitation of auricular defect: a clinical report. *Prosthet Orthot Int* 2012 Oct;27(3):240-244.