

## CASE REPORT

# Effective Management of Periodontal Intraosseous Defects using combination of Bioactive Glass + Platelet-rich Fibrin: A Clinical and Radiographic Evaluation

Madhu Singh Ratre, Sumbul Nasir, Shaleen Khetarpal, Manish Verma

## ABSTRACT

Periodontitis is an infectious disease which causes loss of periodontal supportive tissue, and ultimately tooth loss. Regeneration of lost periodontal tissues is the chief goal of the periodontal therapies. Application of various bone grafts with and without combination of other materials/techniques has been shown improvement in clinical outcomes. Platelet rich fibrin (PRF) is a second generation platelet concentrate which releases growth factors, promoting regeneration. In the literature the combination of PRF and bioactive glass is been explored extensively. Hereby we present and discuss the successful management of periodontal intraosseous defects in two case reports by placement of combination of PRF and bioactive glass. There was significant clinical and radiographic outcomes in both the cases after one year of follow-up.

**Keywords:** Alloplastic bone graft, Bioactive glass, Growth factors, Intraosseous defect, Periodontal Regeneration, Platelet Rich Fibrin (PRF).

**How to cite this article:** Ratre MS, Nasir S, Khetarpal S, Verma M. Effective Management of Periodontal Intraosseous Defects using combination of Bioactive Glass + Platelet-rich Fibrin: A Clinical and Radiographic Evaluation. *Int J Prev Clin Dent Res* 2018;5(2):98-101.

**Source of support:** Nil

**Conflict of interest:** None

## INTRODUCTION

The primary goal of periodontal regeneration therapy is to regain all the periodontal tissues lost by periodontal diseases. Several techniques and their combinations have been employed to achieve this goal including root conditioner, bone grafts, guided tissue regeneration, growth factors, and stem cell.<sup>[1]</sup>

Professor

Department of Periodontology, Government College of Dentistry Indore, Indore, Madhya Pradesh, India

**Corresponding Author:** Dr. Madhu Singh Ratre, Department of Periodontology, Government College of Dentistry Indore, Indore, Madhya Pradesh, India. e-mail: smadhu16feb@yahoo.co.in

Bone graft materials are extensively used and explored in periodontal reconstruction procedures. Bioglasses are alloplastic bone substitutes, composed of  $\text{SiCaONa}_2\text{OP}_2\text{O}_5$ , which induces a biological response at the interface of materials resulting in a bond between tissue and graft particles. On exposure to tissue fluids, a double layer of silica gel and calcium phosphate has formed on their surfaces. This layer promotes absorption, and concentration of proteins used by osteoblasts to form an extracellular bone matrix which stimulates bone formation as described by Hench *et al.*, in 1972.<sup>[2]</sup> These properties make it a potential bone graft material to be used in periodontal regenerative procedures.<sup>[3]</sup>

The regenerative properties of platelet concentrates have been noticed in the 70s by some researchers.<sup>[4]</sup> Choukroun *et al.*, 2001,<sup>[5]</sup> developed a second generation platelet concentrate and named it platelet-rich fibrin (PRF). PRF is an autologous fibrin matrix rich in platelet and leukocyte cytokines. It contains growth factors which play an important role in collagen production, cell mitosis, blood vessel growth, and recruitment of other cells during healing and regeneration.<sup>[6]</sup> PRF has been evaluated and found to be effective for the management of furcation<sup>[7]</sup> and intrabony defects<sup>[8]</sup> by various researchers.

In same direction, combination of PRF with different bone graft materials has shown promising results compared with techniques used alone.<sup>[9]</sup> Recently, researchers have observed improved periodontal regeneration by applying a combination of bioactive glass with PRF.<sup>[10]</sup> Hence, the present clinical case reports were aimed to discuss the clinical and radiographic outcomes of combining PRF and bioactive glass in the management of periodontal intrabony defects.

## CASE REPORT

### Case 1

A 38-year-old male patient, systemically healthy, non-smoker reported to the Government Dental College and Hospital, Indore, Department of Periodontology with a chief complaint of loosening of teeth in the lower front tooth region. On clinical examination, periodontal probing depth (PPD) of 7 mm [Figure 1a] and Grade 2 mobility were present in relation to the right mandibular

lateral incisor. Radiographically, angular bone loss was extended up to the apical third of the distal surface of the same [Figure 1e].

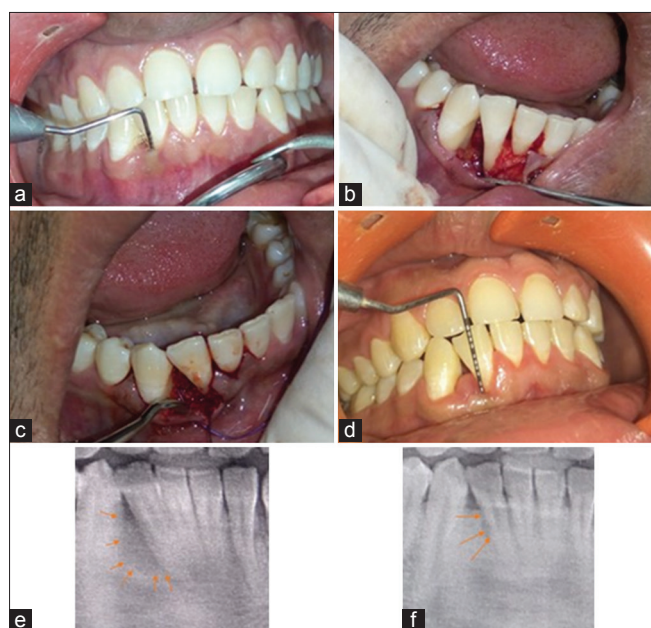
**Case 2**

A 42-year-old male patient, systemically healthy, non-smoker reported to the Government Dental College and Hospital, Indore, Department of Periodontology with a chief complaint of pus discharge from the left lower back tooth region. On clinical examination, a sinus opening and a PPD of around 13 mm [Figure 2a] were observed in relation to mandibular right first molar. Intraoral periapical radiograph angular bone loss was found extending up to the apical third of the distal surface of the same [Figure 2e].

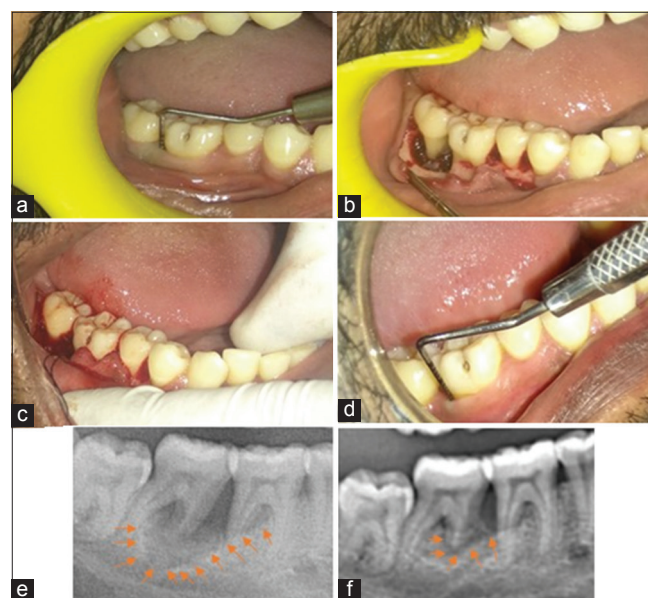**Management**

A presurgical evaluation was done with all the required hematological investigations. After Phase I therapy, regenerative surgical procedure was planned with combination of PRF and bioactive glass and explained to the patient. After consent, a full-thickness flap was elevated under local anesthesia. Complete debridement of the surgical site was done [Figures 1b and 2b]. 10 ml of blood was retracted from the antecubital fossa of the arm and blood was centrifuged at 3000 rpm for 10 min and PRF was formed [Figure 3a and b].<sup>[5]</sup> The mixture of PRF and bioactive glass [Figure 3c] was placed at the defect site [Figure 1c and 2c]. The mucoperiosteal

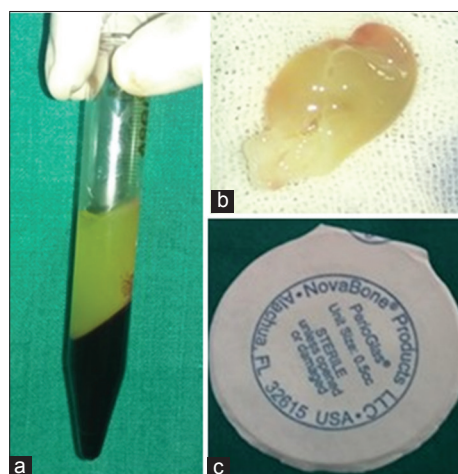
flap was repositioned and secured with interrupted sutures using 4-0 restorable suture. A surgical dressing was used to cover the surgical site. The patient was prescribed with amoxicillin 500 mg 4 times per day and ibuprofen 400 mg 3 times per day for 5 days, along with chlorhexidine digluconate rinses (0.12%) twice daily for 2 weeks. Periodontal dressing and sutures were removed 2 weeks postoperatively. The patient was recalled at 1 month, and then every 3 months, till 1 year for post-operative examination and maintenance. Oral hygiene instructions were reinforced at every visit. There was a significant improvement in periodontal status in both the cases presented. The PPD was reduced from 7 mm to 4 mm in case 1 [Figure 1d] and 13 mm



**Figure 1:** (a) Pre-operative (PPD). (b) Intra-operative photograph. (c) Insertion of mixture of PRF and bioactive glass at the surgical site. (d) One year Post-operative (PPD). (e) Pre-operative radiograph. (f) Post-operative radiograph



**Figure 2:** (a) Pre-operative (PPD). (b) Intra-operative photograph. (c) Insertion of mixture of PRF and bioactive glass at the surgical site. (d) One year Post-operative PPD. (e) Pre-operative radiograph. (f) 1 year post-operative radiograph



**Figure 3:** (a) PRF. (b) PRF membrane. (c) Bioactive glass (Perioglas)

to 5 mm [Figure 2d] in case 2. Radiograph shows significant bone fill at the site of angular bone defect in both the cases [Figures 1f and 2f]. Tooth mobility was decreased from Grade 2 to Grade 0 in case 1 while the sinus was completely healed in case 2.

## DISCUSSION

In the present case report, both the patients have shown improved clinical results with significant reduction in PPD, gain in clinical attachment level (CAL), and reduced mobility and bone fill. Although autogenous bone graft, particularly of cancellous nature, is the ideal graft for regenerative therapies, as it possesses properties of osteogenesis, osteoinduction, osteoconduction, and osteopromotion. However, the inherent limitations like an extra surgical site, technique sensitivity, increased procedural time, and associated morbidity, pain & discomfort limit their wide application. Therefore, the usage of synthetic graft has increased day by day. Bioactive glass is synthetic alloplastic material, which is of osteoconductive and/or osteopromotive in nature. Its bone regenerative and antibacterial potential have been explained by Hench.<sup>[2]</sup> In a 5-year clinical and radiographic comparative study,<sup>[3]</sup> the repair response of bioactive glass synthetic bone graft particles and bioabsorbable membrane was evaluated by a group of researchers in the treatment of human periodontal osseous defects. They concluded significant improvement in PPD and CAL. In another study, bioactive glass is found to be effective treatment option for the reconstruction of intrabony periodontal defects as it led to statistically significant improvements in the clinical and radiographic parameters.<sup>[11]</sup>

Growth factors are important signaling molecules, which regulate the healing cascade by playing a role in mitogenesis directed migration of cells and their metabolism to accomplish wound healing and regeneration.<sup>[12]</sup> The autologous platelet concentrates are the rich source of growth factors. With the better understanding of molecular basis of healing, its application in enhancing the wound repair has received immense attention by the researchers. PRF has significant advantages over other platelet concentrates such as no additive anticoagulant, simple to prepare, lack antigenicity, and cost-effective. Studies have demonstrated enhanced regenerative outcomes of PRF in intrabony defects in generalized chronic periodontitis patients when compared to open flap debridement (OFD).<sup>[8]</sup> The mean PPD reduction was greater in the PRF group ( $4.55 \pm 1.87$  mm) than in the OFD ( $3.21 \pm 1.64$  mm), whereas the mean CAL gain was also greater in the PRF group ( $3.31 \pm 1.76$ ) compared to the OFD ( $2.77 \pm 1.44$  mm). Furthermore,

a significantly greater percentage of mean bone fill was found in the PRF ( $48.26\% \pm 5.72\%$ ) compared to the OFD ( $1.80\% \pm 1.56\%$ ).

Combination of bone graft and PRF is being assessed in several studies recently.<sup>[12,13]</sup> In which a comparison was done for the clinical effectiveness of the combination of PRF and bioactive glass putty and bioactive glass putty alone as regenerative techniques for intrabony defects in humans. The results of that study showed both the groups bioactive glass putty alone and the combination of PRF and bioactive glass putty is effective in the treatment of intrabony defects.

## CONCLUSION

The results of the present case reports are in accordance with the aforementioned studies. Significant reduction in PPD, gain in CAL, and bone fill could be achieved with application of the combination therapy of PRF and bioactive glass in comparison from baseline. Hereby, we suggest that this combination is an effective approach for the regenerative management of intrabony defects. Long-term and controlled clinical trials should be performed to further establish the efficacy of combination of PRF with bioactive glass.

## REFERENCES

1. Polimeni G, Xiropaidis AV, Wikesjö UM. Biology and principles of periodontal wound healing/regeneration. *Periodontology* 2000 2006;41:30-47.
2. Hench LL, Splinter RJ, Allen WC, Greenlee TK Jr. Bonding mechanism at the interface of ceramics prosthetic materials. *J Biomed Mater Res Symp* 1972;2:11741.
3. Mengel R, Schreiber D, Flores-de-Jacoby L. Bioabsorbable membrane and bioactive glass in the treatment of intrabony defects in patients with generalized aggressive periodontitis: Results of a 5-year clinical and radiological study. *J Periodontol* 2006;77:1781-7.
4. Ross R, Glomset J, Kariya B, Harker L. A platelet-dependent serum factor that stimulates the proliferation of arterial smooth muscle cells *in vitro*. *Proc Natl Acad Sci* 1974;71:1207-10.
5. Choukroun J, Diss A, Simonpieri A, Girard MO, Schoeffler C, Dohan SL, et al. Platelet-rich fibrin (PRF): A second-generation platelet concentrate. Part IV: Clinical effects on tissue healing. *Oral Surg Oral Med Oral Pathol Oral Radiol Endod* 2006;101:56-60.
6. Kiran NK, Mukunda KS, Raj TN. Platelet concentrates: A promising innovation in dentistry. *J Dent Sci Res* 2011;21:50-61.
7. Sharma A, Pradeep AR. Autologous platelet-rich fibrin in the treatment of mandibular degree II furcation defects: A randomized clinical trial. *J Periodontol* 2011;82:1396-403.
8. Sharma A, Pradeep AR. Treatment of 3-wall intrabony defects in patients with chronic periodontitis with autologous platelet-rich fibrin: A randomized controlled clinical



- trial. J Periodontol 2011;82:1705-12.
9. Lekovic V, Milinkovic I, Aleksic Z, Jankovic S, Stankovic P, Kenney EB, *et al.* Platelet-rich fibrin and bovine porous bone mineral vs. Platelet-rich fibrin in the treatment of intrabony periodontal defects. J Periodontol Res 2012;47:409-17.
  10. Ashawan PJ, Zade RM. Comparative evaluation of bioactive glass bone graft material with platelet rich fibrin and bioactive glass bone graft material alone for the treatment of periodontal intrabony defects: A clinical and radiographic study. Int J Res Med Sci 2017;4:3288-94.
  11. Vishakha G, Anoop K, Ranjan M, Ranjit S. Evaluation of the efficacy of a bioactive synthetic graft material in the treatment of intrabony periodontal defects. J Indian Soc Periodontol 2013;17:104-10.
  12. Nevins M, Giannobile WV, McGuire MK, Kao RT, Mellonig JT, Hinrichs JE, *et al.* Platelet-derived growth factor stimulates bone fill and rate of attachment level gain: Results of a large multicenter randomized controlled trial. J Periodontol 2005;76:2205-15.
  13. Naqvi A, Gopalakrishnan D, Bhasin MT, Sharma N, Haider K, Martande S. Comparative evaluation of bioactive glass putty and platelet rich fibrin in the treatment of human periodontal intrabony defects: A randomized control trial. J Clin Diagn Res 2017;11:ZC09.