

ORIGINAL ARTICLE

Prevalence of Types of Soft Palate in Indian Population in Wardha Region, Maharashtra, India: An *in vivo* Study

¹Sweta Pisulkar, ²Rajiv Bhola, ³Ashok J Pakhan, ⁴Surekha R Godbole, ⁵Trupti Dahane

ABSTRACT

An area of soft tissue along the junction of the hard and soft palate on which pressure, within physiologic limits of the tissues, can be applied by a denture to aid in its retention can be defined as the posterior palatal seal (PPS). The functions of PPS are to provide retention, to prevent food from getting under the base of the denture, to diminish the gag reflex, to make the denture less conspicuous to the tongue, and to counteract denture warpage due to dimensional changes during the curing process by providing a thick border. The location and recording of the PPS, although being a very significant step, are still a frequently neglected procedure, because of lack of proper knowledge. Clinically, various different locations of the vibrating line resulted from different methods. This study was therefore designed to evaluate if the posterior and anterior vibrating lines could be distinguished as separate lines of flexion and to evaluate type of soft palate among Indian population, i.e., Wardha population. The following conclusions were made, from the above study: (a) Two separate lines of flexion could be located in Indian population, when the appropriate action was elicited for the posterior and anterior vibrating lines; (b) in flat group (group III), the vibrating line was farther posteriorly (i.e., closer to a line joining both hamular notches), resulting in the broadest PPS area, whereas the posterior extension of the PPS area in the deep vault was less than in groups II (medium) and III (deep). (c) In group III (flat), the width of the PPS area was greater than in groups I (deep) and II (medium). This width was the least in group I (deep).

Keywords: Anterior, Hamular notch, Posterior palatal seal, Posterior vibrating lines.

How to cite this article: Pisulkar S, Bhola R, Pakhan AJ, Godbole SR, Dahane T. Prevalence of Types of Soft Palate in Indian Population in Wardha Region, Maharashtra, India: An *in vivo* Study. *Int J Prev Clin Dent Res* 2018;5(1):37-40.

Source of support: Nil

Conflict of interest: None

^{1,5}Associate Professor, ²Assistant Professor, ³Professor and Dean, ⁴Professor and Head

¹⁻⁵Department of Prosthodontics, Sharad Pawar Dental College & Hospital, Datta Meghe Institute of Medical Science (Deemed to be University), Wardha, Maharashtra, India

Corresponding Author: Sweta Pisulkar, Associate Professor Department of Prosthodontics, Sharad Pawar Dental College & Hospital, Datta Meghe Institute of Medical Science (Deemed to be University), Wardha, Maharashtra, India, Phone: +919881215746 e-mail: drsweta15@gmail.com

INTRODUCTION

The role of the PPS in the quality of retention of the maxillary complete denture is very well established. An area of soft tissue along the junction of the hard and soft palate on which pressure, within physiologic limits of the tissues, can be applied by a denture to aid in its retention may be defined as the PPS (Fig. 1). The function of PPS is to provide retention, hygiene, diminish the gag reflex, esthetics by virtue of making the sunken border less conspicuous to the tongue, and to counteract denture warpage because of dimensional changes during the curing process by providing an appropriate thick border.¹⁻⁴

The location and recording of the PPS are a very important yet frequently neglected procedure due to various controversial facts regarding the anterior and posterior vibrating line concepts. Most authors agree to the fact that the retention and stability of a maxillary complete denture are contributed significantly by this seal.⁶⁻⁹

Determination of the PPS is the responsibility of the prosthodontist and the dental surgeon and should never be delegated to auxiliary personnel.⁴⁻⁶ Location of the vibrating line totally relies on visual observation. For determining the location of the vibrating line, the currently used techniques are based on^{3,5,7}: (1) Phonation of "ah" sound, (2) the palpatory method, (3) the Valsalva maneuver (nose-blowing method), and (4) the swallowing method. Clinically, different locations of the vibrating line may result from different methods. The location of vibrating line in an individual observed by the nose-blowing method is more anterior compared with the vibrating line

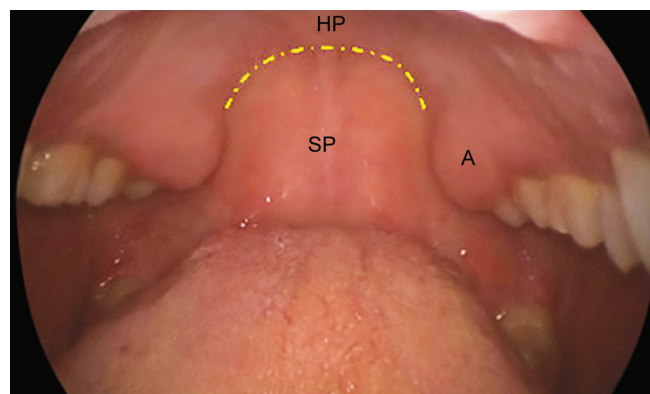


Fig. 1: Posterior palatal seal area

visualized by the phonation method.⁸ A survey on various methods taught in dental schools for determining the PPS region in the United States and Canada was conducted by Chen et al.⁵

They concluded that (1) the combination of the available data was most frequently taught clinical methods for location of the vibrating line; (2) the literature also states that the phonation of the “ah” sound was the most popular single method taught for locating the vibrating line; (3) there is one vibrating line that can be located for each individual person and this was taught by majority of the dental schools; and (4) the dental schools that teach the concept of two vibrating lines relate the posterior flexion line to the distal termination of the maxillary denture. The evidence-based literature describes that most of the dental schools give no or little significance to the marking of the anterior vibrating line teaching the concept of two vibrating lines. It is either marked arbitrarily anterior to the posterior vibrating line or, most often, not marked at all. Silverman⁷ in his research determined that the distance between the vibrating lines varies from 4.12 mm, with an average of 8.2 mm. However, there are no evidential subsequent studies that determine whether two separate lines of flexion can be distinguished for the anterior and posterior vibrating lines.

The present study was, therefore undertaken to evaluate if the posterior and anterior vibrating lines could be distinguished as separate lines of flexion and to determine soft palate type among Indian population, i.e., Wardha population. Classification of soft palate: Boucher^{3,4} has classified soft palate based upon the angle that the soft palate makes with the hard palate. According to him, there are three classes of soft palate configuration. These soft palate classifications are determined when the patient is in an upright position with the head held erect. It has been observed that positional changes of the head and physiologic functioning of the tongue can be an influential factor in soft palatal placement.

Class I: Soft palate that is rather horizontal, as it extends posteriorly with minimal muscular activity. The anterior and posterior vibrating lines are separated by a considerable amount of distance in millimeters. This allows for a particularly wide PPS (Fig. 2).

Although it is not very deep, it is the most favorable configuration since more tissues can be covered, yielding a potentially more retentive denture base. Most acute contour in relation to the hard palate is indicated in class III, necessitating marked elevation of the musculature to create velopharyngeal closure. A high v-shaped palatal vault is usually seen in conjunction.

The PPS is less than class I, as there is a greater elevation of the soft palatal musculature in function. It is

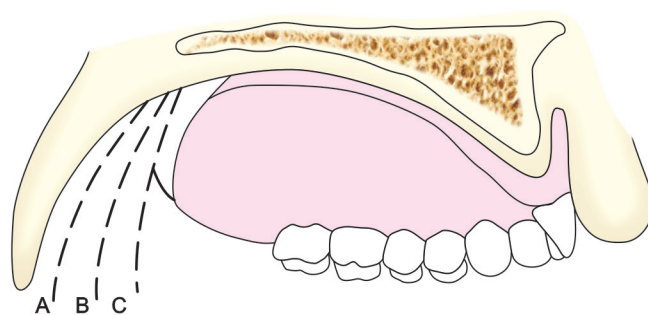


Fig. 2: Types of soft palate

usually deeper than class I. Those palatal contours that lie somewhere between class I and III are designated as class II. House^{1,3-5} further modified this classification as follows (House modification): Class I: Flat modified butterfly with the maximum anteroposterior width 3 to 4 mm; class II: High modified butterfly 2 to 3 mm with maximum anteroposterior width 2 to 3 mm; class III: Intermediate: Intermediate is a bead type and as the name suggests, it is a bead type with a minimum width at the posterior palatal spine.

MATERIALS AND METHODS

This prospective study was conducted in the Department of Prosthodontics, Sharad Pawar Dental College, Sawangi (Meghe), Wardha.

Totally 150 undergraduate students were selected as the subjects. Alginate impression materials were used to make preliminary impressions. In each subject, marking of anterior vibrating line and posterior vibrating line was done. The subject was then instructed to say “ah” in a normal unexaggerated manner. They were then directed to perform the above maneuvers whenever the instructions to do so were given. In the study, observations recorded were made by the subject experts who were previously oriented to the predetermined rating scale. The PPS area was properly isolated with a gauze sponge. The subject was further asked to perform the first maneuver (saying ah in an unexaggerated manner).

The hamular notch was located by palpation and marked using an indelible lilac-colored pencil. The beginning of the line of motion of the soft palate was marked with the indelible pencil by the observer (Fig. 3). The impression was dried and then placed in the mouth by the study coordinator to transfer the marking. The lilac marking on the palate was then wiped with the help of gauze. The study coordinator confirmed the anterior vibrating line by using the palpation method wherein a T-burnisher was used. The impression was poured and cast was recovered.

The comparison of the lines was made on the on the cast and was checked for proper position of PPS, as it

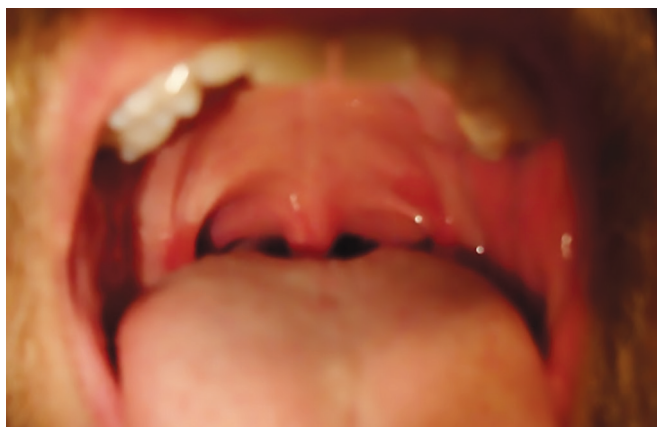

Fig. 3: Average area of PPS depends on type of soft palate

changes with the type of soft palate form. The data thus obtained were tabulated and results were obtained.

RESULTS

The posterior and anterior lines of flexion were marked with the specific techniques described for the posterior and anterior vibrating lines in each case, and the soft palate type was noted in 150 subjects. It is depicted in Table 1 and Graph 1.

DISCUSSION

In the present study, according to the observations, it is very well accepted that the posterior border of the maxillary denture should end at the posterior vibrating line, thus justifying the fact that the anterior and posterior vibrating

lines aid in the retention of the denture by placing pressure within physiological limits.⁸⁻¹⁰

The findings of the study are in coherence with the findings suggested by Silverman,⁷ who also described the techniques for recording the same first described anterior and posterior vibrating lines. The findings of the study also justify the fact that the PPS area lies between these anterior and posterior vibrating lines.

Careful observation and palpation of the tissue are of utmost necessity in order to correctly locate these lines, as the locations of these lines vary with the contour of the soft palate. Also, to determine their compressibility in width and depth, the palatal tissues anterior to the posterior border need to be palpated with a blunt instrument.

The anterior vibrating line usually coincides with the termination of the glandular tissues.^{1,2,11-13} Thus, a combination of the visual and palpatory methods was used in the present study. Although Silverman stated an average dimension of 8.2 mm of the vibrating area, it sometimes in an individual may vary according to the configuration of the soft palate (Fig. 2).

The present study also states that the palatal seal area can be several millimeters short of tissue coverage, which can have a direct effect upon the retentive potential of the denture base by use of this average dimension. For example, a class I soft palate configuration allows for a wide PPS, but one that is not very deep, on the contrary, a deeper but smaller PPS area in a class III soft palate.^{1,13} The zone of transition between no movement of the tissues overlying the hard palate and some movement of the tissues of the soft palate is demarcated by the anterior vibrating line. It can be located by visualization and palpation of the hamular processes.

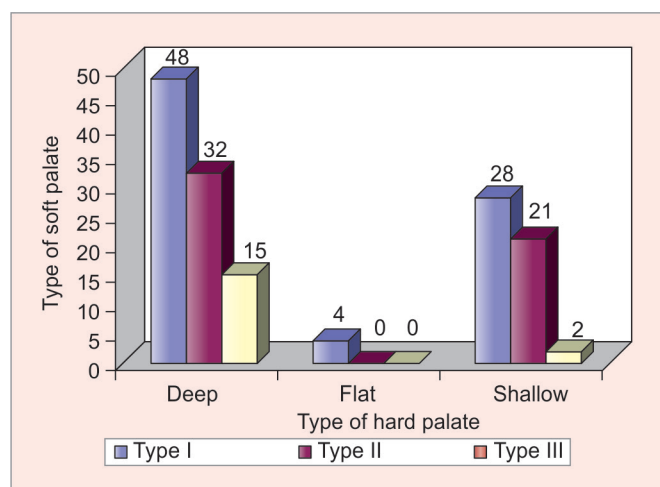
The observations of the present study are also in coordination with the findings that the fovea palatine may be used as a guide in locating the anterior vibrating line, but should not be used as a definite location to which the posterior border of the denture should be extended. The anterior border of the PPS area can be determined by the anterior vibrating line. It is generally not a straight line between the hamular processes, but reflects the projection of the posterior nasal spine along the posterior border of the palatine bone. The anterior vibrating line can be visualized by asking the patient to say "ah" in short vigorous bursts or by asking the patient to perform the Valsalva maneuver. The posterior vibrating line lies in the area of the junction of the aponeurotic portion of the soft palate and the muscular portion of the soft palate.

The posterior vibrating line can be visualized by instructing the patient to say "ah" in a normal unexaggerated fashion and is the maximum posterior extension of the PPS. The undergraduate students taking part in the study were not aware of the exact method that could

Table 1: Correlation of type of hard palate with type of soft palate

	Type I	Type II	Type III	χ^2 -value	p-value
Deep	48	32	15	8.36	0.06 NS,
Flat	4	0	0		p>0.05
Shallow	28	21	2		

NS: Not significant



Graph 1: Correlation of types of hard palate with soft palate

elicit movement at the anterior and posterior vibrating lines, thereby eliminating the bias in locating the lines that could possibly have ensued from awareness of the same. There was no subconscious attempt at separating the new line from the previous one and it was ensured by erasing each line previously marked before marking the next. The anterior vibrating line located by the palpatory method showed a general tendency to be slightly anterior to the line of flexion located by the Valsalva maneuver. This might happen as a result of the palpatory method which usually tends to locate the anatomical junction of the hard and soft palate as opposed to the physiologic line of flexion at the junction of the movable and immovable parts of the soft palate located by the Valsalva maneuver. As the sample size considered in the study might seem a little short for evidence-based observations (for the purpose of the pilot study), a statistical conclusion was not made. However, the graphical representation of the results has been illustrated below. There is further scope for extension of the findings gathered from the present study to a larger sample for achieving more accurate outcomes.

CONCLUSION

Based upon the findings of the present study, the following conclusions were made: (1) The anterior and posterior vibrating lines could be located in population as two separate lines of flexion when the appropriate action was elicited for each of them. (2) In group III (flat), the vibrating line was farther posteriorly (i.e., closer to a line joining both hamular notches), resulting in the broadest PPS area, whereas in the deep vault, the posterior extension of the PPS area was less than in groups II (medium)

and III (deep). (3) The width of the PPS area in group III (flat) was greater than in groups I (deep) and II (medium). In group I (deep), this width was the least.

REFERENCES

1. Hardy IR, Kapur KK. Posterior border seal: its rationale and importance. *J Prosthet Dent* 1958 May;8(3):386-397.
2. Ettinger RL, Scandrett FR. The posterior palatal seal: a review. *Aust Dent J* 1980 Aug;25(4):197-200.
3. Calomeni AA, Feldmann EE, Kuebker WA. Posterior palatal seal location and preparation on the maxillary complete denture cast. *J Prosthet Dent* 1983 May;49(5):628-630.
4. Weintraub GS. Establishing the posterior palatal seal during the final impression procedure: a functional approach. *J Am Dent Assoc* 1977 Mar;94(3):505-510.
5. Chen MS, Welker WA, Pulskamp FE, Crosthwaite HJ, Tanquist RA. Methods taught in dental schools for determining the posterior palatal seal region. *J Prosthet Dent* 1985 Mar;53(3):380-383.
6. Laney WR, Gonzalez JB. The maxillary denture: its palatal relief and posterior palatal seal. *J Am Dent Assoc* 1967 Nov;75(5):1182-1187.
7. Silverman SI. Dimensions and displacement patterns of the posterior palatal seal. *J Prosthet Dent* 1971 May;25(5):470-488.
8. Nimmo A. Correction of the posterior palatal seal by using a visible light-cured resin: a clinical report. *J Prosthet Dent* 1988 May;59(5):529-530.
9. Lauciello FR, Conti SP. A method of correcting the posterior palatal seal area of a maxillary complete denture. *J Prosthet Dent* 1979 Dec;42(6):690-692.
10. Ansari IH. Establishing the posterior palatal seal during the final impression stage. *J Prosthet Dent* 1997 Sep;78(3):324-326.
11. Carroll EA, Shaffer FW. Redefining the posterior palatal seal on a complete denture. *J Prosthet Dent* 1980 Jan;43(1):105-107.
12. Craig RG, Berry GC, Peyton FA. Physical factors related to denture retention. *J Prosthet Dent* 1960 May-Jun;10(3):459-467.
13. Lawson WA. Fundamental principles of full denture prosthetics. *Dent Clin North Am* 1965;10(4):496.