

CASE REPORT

Functional Jaw Orthopedic Correction of Class II Malocclusion: A Novel Approach

¹Vijay Bagul, ²Sameer Parhad, ³Manish L Thadani, ⁴Vishal Dhanjani, ⁵Ketan Vora, ⁶Bipin Upadhyay

ABSTRACT

Class II malocclusions may present with skeletal features of mandibular retrognathism, midface protrusion, and dental features of distal step molar relation. An unusually large overjet and/or variable combinations of these features are common in class II malocclusions. Europeans have tried to grow deficient and repositioned mandibular with the help of various remarkable and fixed appliances called myofunctional therapy, viz., Frankel, Bionator, Twin Block, etc. Although timing of treatment, mode of their action, treatment benefits, and mechanism of craniofacial adaption have been researched extensively, the subject of functional appliances has always been a matter of discussion with conflicting views. The article provides an insight into early diagnosis and nonextraction fixed mechanotherapy approach for treatment of complex malocclusions.

Keywords: Class II malocclusions, Functional jaw orthopedic, Skeletal malocclusion twin block.

How to cite this article: Bagul V, Parhad S, Thadani ML, Dhanjani V, Vora K, Upadhyay B. Functional Jaw Orthopedic Correction of Class II Malocclusion: A Novel Approach. *Int J Prev Clin Dent Res* 2018;5(1):96-99.

Source of support: Nil

Conflict of interest: None

INTRODUCTION

This case report aims at providing simple solutions to complex malocclusion problems if diagnosed and

treated amicably without much of differences among all patients. Orthodontic treatment requires a long duration and visible results are seen only at the end of 18 to 24 months, which makes patients deter from taking up the treatment.^{1,2}

But good motivated patient if treated well can really improve the compromised esthetics, negative body image, psychological disturbance that could manifest as poor performance in school, poor interpersonal, workplace relationship, poor marital alliance, and so on.³⁻⁵

For some people oral health-related issues can be further affected due to compromised functions of mouth, such as mastication, respiration, and speech in addition to compromised esthetics.

Pretreatment Assessment

An 11.2-year-old female patient studying in school approached our daily outpatient department with shy face and highly upset with her look, as she has been teased at school for forwardly placed upper teeth.

The self-confidence of such kind of patients is being really at the lowest as compared with their peer group. On extraoral examination, upper anterior teeth were severely forwardly placed along with incompetent lip seal, featuring deficient and retrognathic mandible, while intraoral examination showed distal step molar relationship and 7 to 8 mm of overjet and 4 to 5 mm of deep bite (Figs 1A to F).

All clinical examinations got validated with cephalometric analysis and predictable growth spurt was obtained from cervical vertebrae maturity index. As patient was self-motivated and reported at the stage of completely erupted permanent teeth, we promptly tempted to attempt functional jaw orthopedics. Patient's parents also provided valuable history of thumb sucking till age of 8 to 9 years, which was stopped later on. Along with similar presentation on paternal side, genetic predominance for pronounced class II malocclusion was confirmed.

Treatment Objective

Aims and objective of treatment were to take advantage of horizontal growth pattern of mandible along with initial

^{1,2,5,6}Associate Professor, ^{3,4}Private Practitioner

¹Department of Orthodontics and Dentofacial Orthopedics SMBT Dental College & Hospital, Nashik, Maharashtra, India

²Department of Orthodontics and Dentofacial Orthopedics Saraswati-Dhanwantari Dental College & Hospital, Parbhani Maharashtra, India

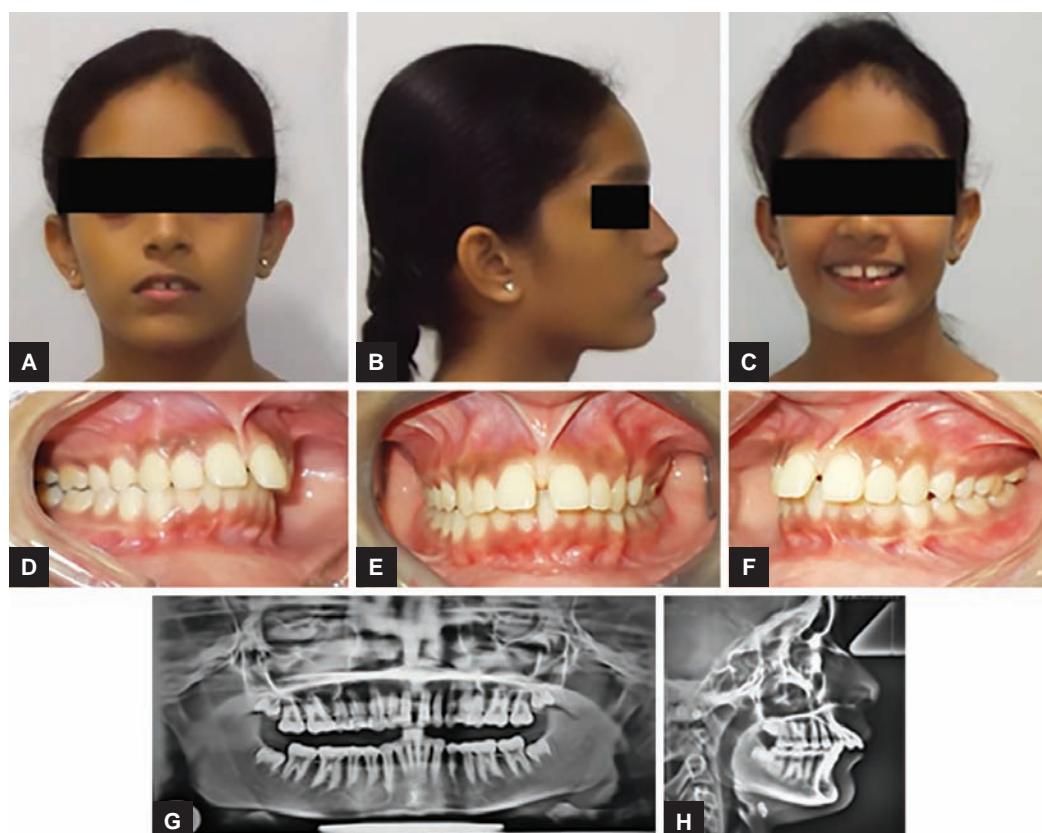
³Department of Orthodontics, Nagpur Dental Clinic, Nagpur Maharashtra, India

⁴Department of Orthodontics, Sure Smile Dental Clinic, Mumbai Maharashtra, India

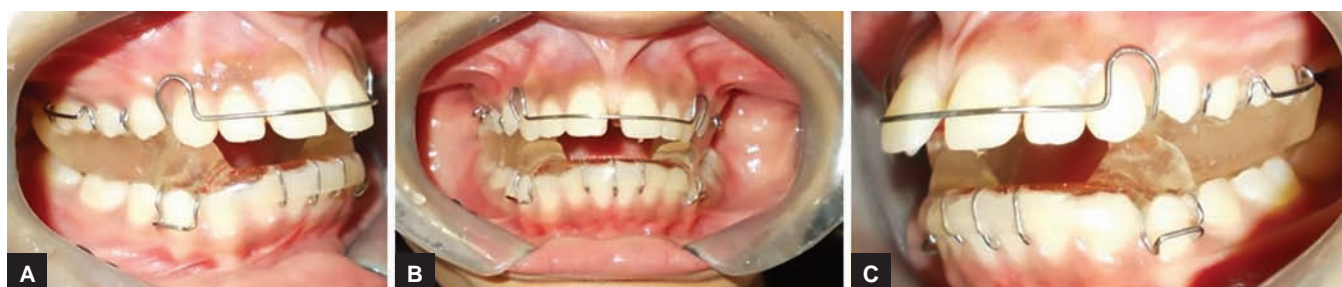⁵Department of Orthodontics and Dentofacial Orthopedics Sinhgad Dental College & Hospitals, Pune, Maharashtra, India

⁶Department of Oral Medicine, Diagnosis and Radiology, SMBT Dental College & Hospital, Nashik, Maharashtra, India

Corresponding Author: Vijay Bagul, Associate Professor Department of Orthodontics and Dentofacial Orthopedics SMBT Dental College & Hospital, Nashik, Maharashtra, India e-mail: vijaybagul2001@gmail.com



Figs 1A to H: Preoperative extraoral and intraoral photographs and X-rays



Figs 2A to C: Twin block appliance by Dr Clark

growth spurt so as to balance the mismatching skeletal bases, followed by fixed mechanotherapy to align and level both arches plus closure of midline diastema.^{3,4} The final objective was to attend patient's distressed unpleasant soft tissue profile.

Treatment Plan

Records and Measurement

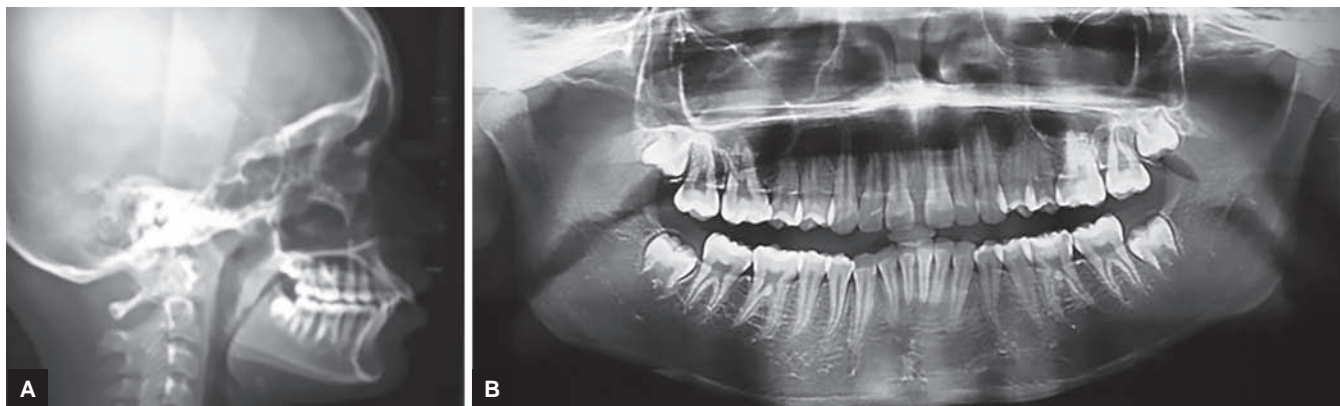
As per the consent of patient after routine dental prophylaxis, study modes were prepared. Model analysis revealed mild Bolton's discrepancy but manageable by simple alignment and leveling of teeth; extraoral as well as intraoral photographs were recorded (Figs 1G and H).

Bite Registration

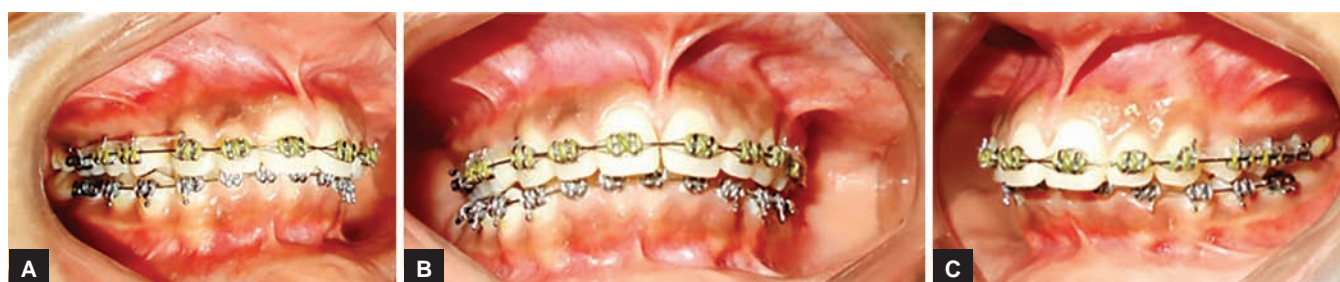Mandibular advancement bite registration along with vertical opening was obtained until mandibular muscles, especially mentalis muscle exhibited puckering. Entire bite registration recording was nonstressful and showed immediately positive visual treatment objective.

Appliances Selection

As patient was cooperative and we have predicted excellent compliance, we chose removable Twin Block appliance as two separate blocks for upper and lower jaws (Fig. 2).^{6,7} Although plethora of functional appliances were available, we followed standard protocol of correcting skeletal bases followed by fixed mechanotherapy.



Figs 3A and B: Postoperative X-rays



Figs 4A to C: Fixed mechanotherapy to settle teeth

TREATMENT

Treatment planning involved two phases:

1. Orthopedic phase
2. Orthodontic phase

Orthopedic Phase

After successful registration of bite, removable acrylic Twin Block appliance was delivered to patient with clear instructions of 16 to 20 hours per day wear. The orthopedic therapy lasted for 6 months and much predicted skeletal jaw base alignment was obtained without much of constraint. A regular wear and super compliance led to pleasing soft tissue profile from unpleasing one.

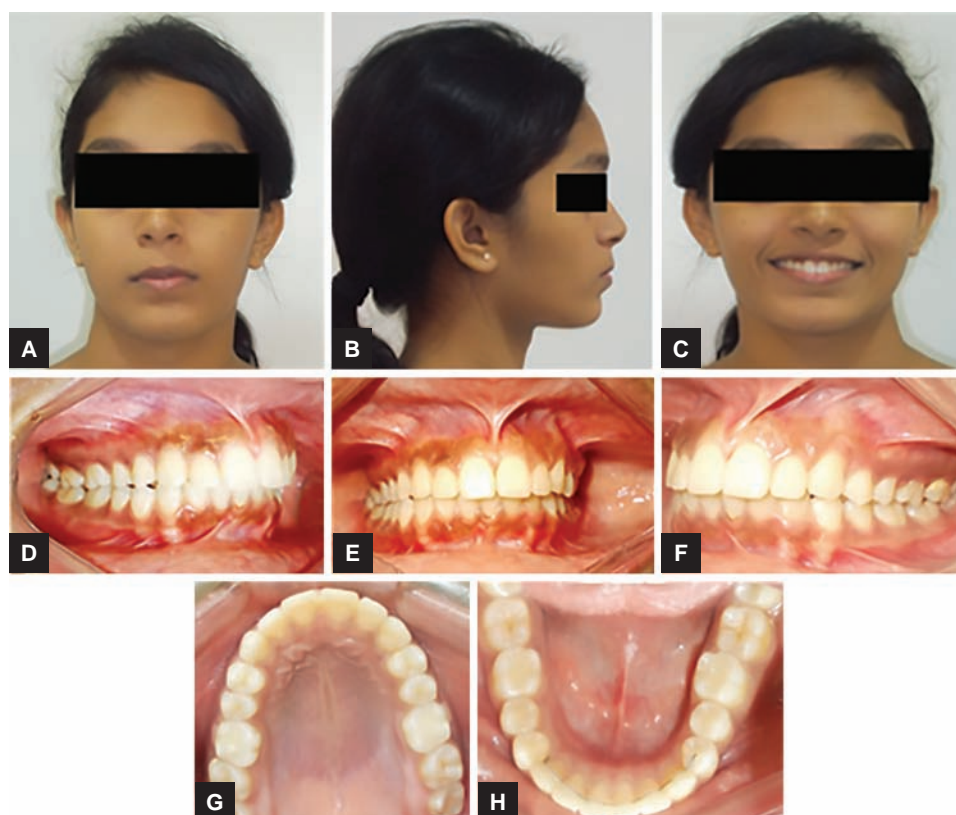Orthodontic Phase

After successful completion of phase I, regular records were obtained in terms of study models, photographs, and X-rays (Fig. 3).

The MBT 0.022" fixed mechanotherapy (metal braces) was initiated for alignment and leveling of arches so as to have good intercuspation and closure of midline diastema (Fig. 4). Bilateral open bite at the end of phase I therapy helped us in resolving deep bite too.

SUMMARY

- Skeletal class II malocclusion is one of the most common reasons for seeking orthodontic treatment.
- Developing class II malocclusion of skeletal origin can be intercepted and treated with functional jaw orthopedics.
- In favorable and compliant cases institution of myofunctional therapy along with fixed mechanotherapy can bring about positive benefits.
- Producing nonextraction and pleasing soft-tissue profile literally outweighs the duration of treatment, which is an enigma of orthodontist as well as patients (Fig. 5).



Figs 5A to H: Postoperative intraoral and extraoral photographs

REFERENCES

1. Moyers RE, Riolo ML, Guire KE, Wainright RL, Bookstein FL. Differential diagnosis of class II malocclusions part I facial types associated with class II malocclusions. *Am J Orthod* 1980 Nov;78(5):477-494.
2. Bishara SE, Ziaja RR. Functional appliances: a review. *Am J Orthod Dentofacial Orthop* 1989 Mar;95(3):250-258.
3. Herren P. The Activator's mode of action. *Am J Orthod* 1959;45:512-527.
4. Schmuth GP. Milestones in the development and practical application of functional appliances. *Am J Orthod* 1983 Jul;84(1):48-53.
5. Baccetti T, Franchi L, Toth LR, Mcnamara JA Jr. Treatment timing for twin block therapy. *Am J Orthod Dentofacial Orthop* 2000 Aug;118(2):159-170.
6. Clark W. Design and management of twin blocks: reflections after 30 years of clinical use. *J Orthod* 2010 Sep;37(3):209-216.
7. McNamara JA Jr. Neuromuscular and skeletal adaptations to altered function in the orofacial region. *Am J Orthod* 1973 Dec;64(6):578-606.