

CASE REPORT

Gingival Veneer: An Esthetic Solution for Gingival Recession

J Iysha Sakeena¹, K Nandakumar², T P Padmakumar³

ABSTRACT

Gingival recessions are the most common esthetic problem usually associated with black triangles. It can be well treated with gingival veneer, which is non-invasive and cost-effective method. Gingival veneer is an important choice in periodontal conditions where anterior teeth are affected with advanced attachment loss and surgical correction is not a feasible option.

Keywords: Black triangle, Esthetics, Gingival recessions, Gingival veneer.

How to cite this article: Sakeena JI, Nandakumar K, Padmakumar TP. Gingival Veneer: An Esthetic Solution for Gingival Recession. *Int J Prev Clin Dent Res* 2018;5(1):S164-166.

Source of support: Nil

Conflicts of interest: None

INTRODUCTION

Periodontal diseases, surgeries, trauma, ridge resorption, and traumatic tooth extraction can result in open interdental spaces, elongated clinical crowns, and altered labiodental/lingual alveolar consonant sound production.^[1] Gingival recession is the most common clinical manifestation of all the oral diseases, as it has a relatively high incidence rate.

Gingival recession can cause loss of interdental papilla and lead to open embrasures, which project in the form of black triangles. The black triangles that appear as a result of gingival recession will distort an amiable smile. The condition can be corrected or managed by two approaches.

1. Mucogingival surgery or gingival plastic surgery, with gingival augmentation coronal to the recession.
2. Gingival replacement with artificial substitutes is more helpful in managing severe gingival recession situations.^[2]

Surgical procedures are invasive, irreversible, technique sensitive, and expensive, with results that are often unpredictable.

Gingival veneers were first described by Emslie in 1955 to restore gingival contour and improve esthetics

following successful treatment of periodontal disease.^[3,4]

They are also known as:

- Gingival masks;^[5]
- Flange prosthesis;^[6] and
- Removable gingival prostheses.^[7]

CASE REPORT

A patient of 34 years presented with the chief complaint of esthetics and phonetic problems in relation to 12, 11, 21, and 22 [Figure 1].

The patient was not willing for surgical treatment, and hence, we opted to survive the teeth by masking the gingival recession by a gingival veneer/gum veneer.

Gum veneer was prepared using heat cure acrylic resin [Figure 2].

Initial preparation was done by Phase I therapy. Later, iPRF was injected into the gingival sulcus of anterior teeth, and periodontal dressing was given and waited for 2 weeks [Figure 3-5].

A custom tray was prepared using impression compound [Figure 6], and impression was taken using alginate [Figure 7]. Model cast was made and wax up was done [Figure 8]. Then, acrylization was done and veneer was prepared using heat cure acrylic.

Gingival veneer was inserted into the patient's mouth [Figure 9]. Retention was achieved with minor interproximal undercuts. The prosthesis was made extremely thin and flexible so as to engage the undercuts [Figure 10].

DISCUSSION

Periodontal disease progression, pocket elimination procedures, and resective osseous surgeries often lead to the creation of recession and the potential for a compromised esthetic outcome, especially in the maxillary anterior region.^[8]

Gingival defects may be treated with surgical or prosthetic approaches. With successful surgical treatment, the result mimics the original tissue contours. Such treatments include minor procedures to rebuild papillae and grafting procedures that may involve not only soft-tissue manipulation but also bone augmentation to support the soft tissue. It is possible to create esthetically pleasing and anatomically correct tissue contours when small volumes of tissue are being reconstructed, but this

¹Post Graduate Student, ²Dean, ³Head

¹⁻³Department of Periodontics, Azeezia Institute of Dental Science and Research, Kollam, Kerala, India

Corresponding Author: J Iysha Sakeena, Post Graduate Student, Department of Periodontics, Azeezia Institute of Dental Science and Research, Kollam, Kerala, India. Email id: iyshasakeena@gmail.com

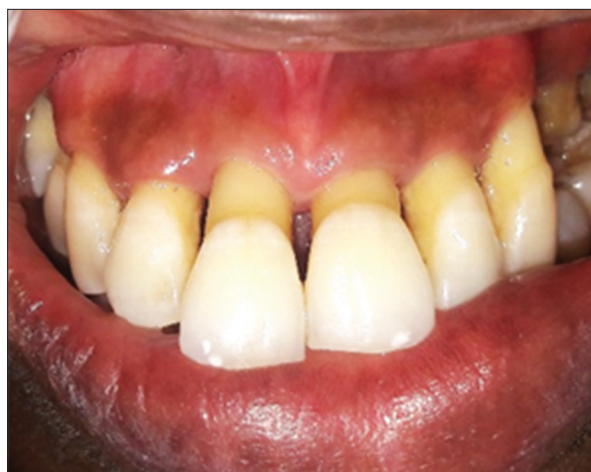

Figure 1: Patient with esthetics and phonetic problems in relation to 12, 11, 14, 21, and 22

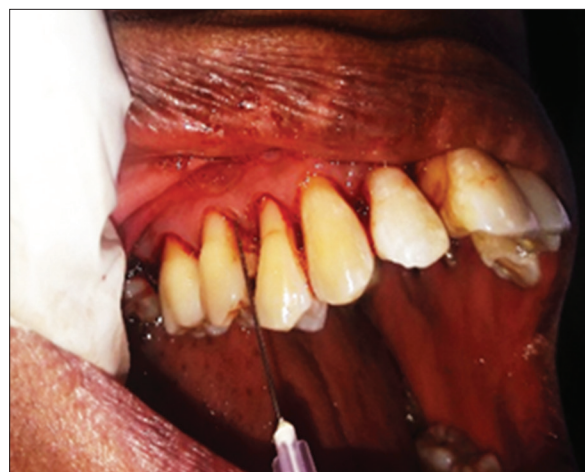

Figure 4: iPRF was injected into the gingival sulcus



Figure 2: Gum veneer was prepared using heat cure acrylic resin

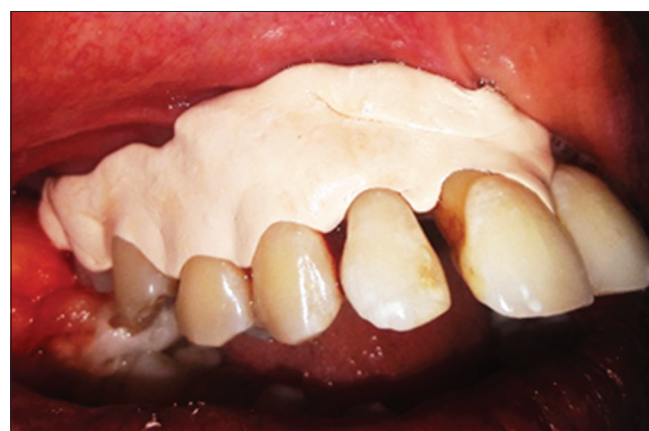

Figure 5: Periodontal dressing was given and waited for 2 weeks

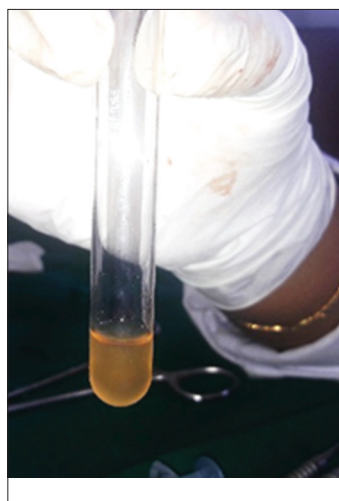

Figure 3: Initial preparation was done by Phase I therapy method is unpredictable when a large volume of tissue is missing.^[9]

Currently, there is no predictable surgical method for correcting esthetic deformities that result from generalized attachment loss. In such situations, gingival prosthesis can be used and various authors have described their uses and methods of construction.^[10-14]

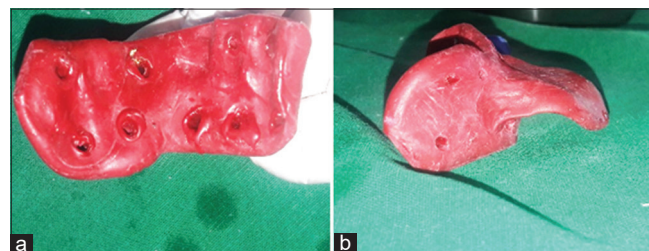


Figure 6: (a and b) Custom tray made of impression compound

In the present case, the patient had a compromised periodontal condition in the maxillary anterior region. After Phase I, the gingiva remained soft, with an average probing pocket depth of 6 mm. The probing depth was observed to be reduced to 4 mm. Then, the recession was covered by gingival veneer. It also has advantage that it can be easily cleaned as it is a removable prosthesis, reduces hypersensitivity, and prevents food lodgement.

CONCLUSION

Periodontal attachment loss, loss of interdental papillae, gingival recession, and tooth hypersensitivity are always

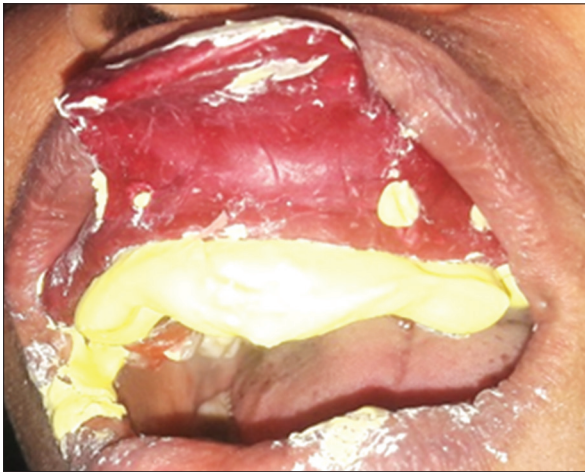


Figure 7: Impression taken using alginate

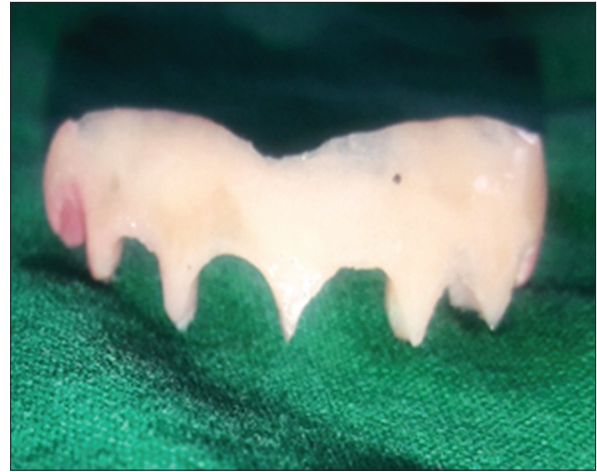

Figure 10: Heat cure acrylic gum veneer

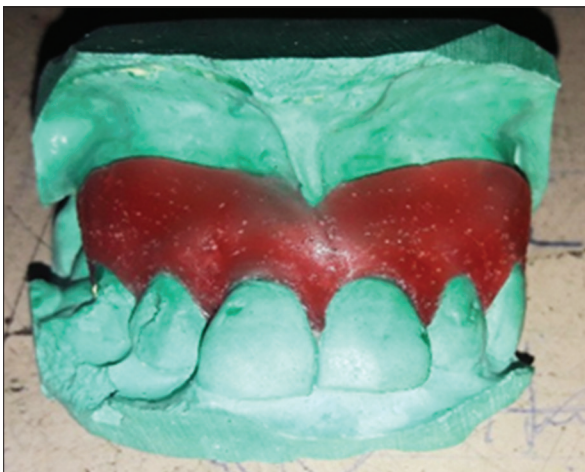

Figure 8: Waxing done

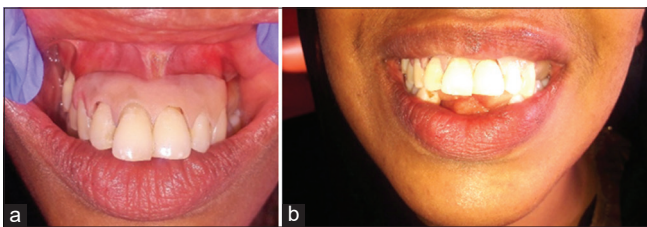


Figure 9: (a and b) Gum veneer placed

a very difficult area to be treated by the periodontist as it is difficult to obtain the desired results along with the acceptance by the patient and to meet the esthetic demands of the patient. Gingival veneer thus can be used in advanced gingival attachment loss and recession by non-invasive method. It is very well accepted by the patient and the clinicians. Hence, these prostheses, in the hands of a trained and experienced clinician, offer predictable

and satisfactory results in the management of esthetic problems.

REFERENCES

1. Mekayarajnanth T, Kiat-amnuay S, Sooksuntisakoonchai N, Salinas TJ. The functional and esthetic deficit replaced with an acrylic resin gingival veneer. *Quintessence Int* 2002; 33:91-4.
2. Shenava A. Gingival mask: A case report on enhancing smiles. *J Oral Res Rev* 2014;6:68-70.
3. Emslie RD. A case of advanced periodontitis complex. *Dent Practitioner* 1955; 5: 432-433.
4. Beckett HA, Wright PS. Construction of a gingival mask in association with an implant-retained fixed maxillary prosthesis – a case report. *Eur J Prosthodont Rest Dent* 1993; 2: 57-60.
5. Greene PR. The flexible gingival mask: An aesthetic solution in periodontal practice. *Br Dent J* 1998; 184(11): 536-540.
6. Carvalho W, Barboza EP, Gouvea CV. The use of porcelain laminate veneers and a removable gingival prosthesis
7. Reddy MS. Achieving gingival esthetics. *J A D A* 2003;134: 295-304.
8. Barzilay I, Irene T. Gingival prostheses - A Review. *J Can Dent Assoc* 2003;69:74-8.
9. Greene PR. The flexible gingival mask: An aesthetic solution in periodontal practice. *Br Dent J* 1998; 184:536-40.
10. Priest GF, Lindke L. Gingival-colored porcelain for implant supported prostheses in the aesthetic zone. *Pract Periodontics Aesthet Dent* 1998;10:1231-40.
11. Blair FM, Thomason JM, Smith DG. The flange prosthesis. *Dent Update* 1996; 23:196-9.
12. Patil S, Prabhu V, Danane NR. Gingival veneer: Mask the unesthetic. *J Indian Soc Periodontol* 2011;15: 284-7.
13. Sanghavi D, Mallya A, Janam P, Menon RK. Masking the unmasked-gingival veneer. *J Dent Res Rev* 2014;1:28-31.