

CASE REPORT

Management of Oronasal Fistula with Closed Hollow Bulb Obturator: A Case Report

Ritul Patel¹, Viral Kalariya², Parth Thumar³, Prutha Patel⁴

ABSTRACT

Most common complication following the surgical closure of the cleft palate is oronasal fistula this case report describes a case of oronasal fistula habilitated with an obturator, which had good esthetics and considerable function.

Keywords: Oronasal fistula, Obturator, Maxilo facial prosthesis.

How to cite this article: Patel R, Kalariya V, Thumar P, Patel P. Management of Oronasal Fistula with closed Hollow Bulb Obturator. *Int J Prev Clin Dent Res* 2018;5(1):S172-174.

Source of support: Nil

Conflicts of interest: None

INTRODUCTION

The incidence of cleft lip and palate is 1 in 500 live births in Republic of India and majority of these patients are not treated surgically at the appropriate time.^[1] Occurrence of this defects can be 2 types congenital and acquired. Occurrence ranges from 0% to 34% as observed in various studies as a common complication of palatal fistula repair surgery.^[2] Parwaz *et al.* found in there study that the width of 15 mm or more had a significant risk of fistula formation.^[3]

Smith *et al.*^[4] classified the palatal fistula into seven types:

The Pittsburgh fistula classification system.

- Type I - referred to bifid uvula.
- Type II - means fistula in the soft palate.
- Type III - means fistula at junction of the soft and hard palates.
- Type IV - means fistula in the hard palate.
- Type V - indicates that the fistula at junction of the primary and secondary palates.
- Type VI - means lingual alveolar fistula.
- Type VII - means labial alveolar fistula.

The patient with a unilateral or bilateral cleft palate, missing anterior teeth, and a deficient alveolar ridge presents the problem of restoring the missing teeth and the alveolar ridge.

Oronasal fistula causes hypernasality due to escape of air during speech and also may lead to regurgitation of food and fluid to the nasal cavity.^[5] The dentists working in both rural and urban setups are liable to encounter these anomalies almost at every time.

The increasing demand for esthetics in restorations can be met with any of the ceramic restoration systems currently available. However, the esthetic value of a cosmetic restoration should be evaluated against conundrum of ceramic prosthesis likely factors contributing to that are design of a pleasant smile, such as amount of gingival display, gingival architecture, clinical crown dimensions, and tooth position and long-term prognosis with maintain health of other teeth involved.

The major prosthetic treatment to close the soft tissue defects was obturator, removable flange prosthesis, and surgical bone augmentation.

As a conventional procedure when treating cleft palate patients with congenital or acquired defects, obturator permits rehabilitation with a removable partial denture. This system permits the replacement of the missing teeth as well as missing supporting structures necessary for proper function and esthetics.

CASE REPORT

An 34-year-old female was came to the Akshar Dental Care, Moviya, for the prosthetic rehabilitation of the palatal fistula after the primary surgical closure of cleft lip.

Relevant dental history acquired and it revealed that the patient had a congenital cleft lip and palatal fistula. Surgical correction of cleft lip was done at the age of 3 months. At the age of 4 years, primary surgical closure of palatal fistula was given an option, but patient's parents due to some reason opt for surgery. She underwent orthodontic correction of misaligned teeth which was completed. She provided surgical option earlier, but due to financial reason and fear of going under other surgery, she opted prosthetic treatment for speech and esthetic correction to build up confidence in social environment.

^{1,2,3,4}Private Practitioner

¹Department of Oral Surgery, Akshar Dental Care Moviya, Akshar Dental Care and Implant Centre Umreth, Gujarat, India

^{2,3,4}Department of Prosthodontic, Akshar Dental Care Moviya Gujarat, India

⁴Department of Oral Surgery, Akshar Dental Care Moviya, Gujrat, India

Corresponding author: Dr. Ritul Patel, Akshar Dental Care, Mvoiya, Gondal, Rajkot, Gujarat, India.
Phone: +91-7600908813. E-mail: drritulpatel17@gmail.com

Intraoral examination revealed maxilla with a Veau's class III defect^[7] (unilateral cleft lip, alveolus, and hard and soft palate) and missing left lateral incisor. A palatal fistula (Class IV)^[4] measuring 5 mm in diameter was present in the anterior part of the hard palate [Figure 1]. She complained of having the nasal escape of fluids and food through the palatal hole.

Extraoral examination revealed a surgical scar on the upper lip due to previous surgical correction of cleft lip. Her speech was not intelligible with a nasal twang in her voice lacking resonance.

Considering her age and oral conditions, we planned to habilitate with an obturator which would be simple in design, lightweight, removable type but easily maintainable. The patient also provided option of prosthesis - obturator attached to Andrews's bridge (fixed removable) but since the patient does not opt that option as the patient was not ready for extraction of 22^[6]. The principle of the system is similar to any removable prosthesis. This permits access to the underlying tissue for cleansing purposes.

A preliminary impression was made using irreversible hydrocolloid (Zelgan 2002 dust-free easy mixing,

DENTSPLY India Pvt. Ltd., Haryana). The custom tray was fabricated using autopolymerizing acrylic resin (self-cure acrylic repair material, DENTSPLY India Pvt. Ltd., India), and border molding were carried out using green stick impression compound (DPI Pinnacle, tracing stick, Dental Products of India, Mumbai). Final impression was made with light viscosity addition silicone impression material [Figure 2] (Zetaplus, Zhermack, Dentsply Sirona, Italy) and the master cast was fabricated using dental stone (Ultrasone, Kalabhai Karson Pvt. Ltd., India) [Figure 3]. The undesirable undercuts present in the defect were blocked out in wax.

Teeth shape and color approved through the patient. Missing lateral incisor was replaced with two teeth as there was more space. The teeth arrangement was done and tried in the mouth [Figure 4].

This was acrylicized with heat cure acrylic resin. The Adams clasp and triangular clasps made and incorporated into prosthesis [Figure 5]. Finishing and polishing of the removable prosthesis were done and were inserted in the patient mouth. The patient was trained for proper placement and removal of the removable dental prosthesis. The patient was instructed on oral hygiene procedures and proper maintenance of the prosthesis.

On recall, the patient was quite comfortable with the

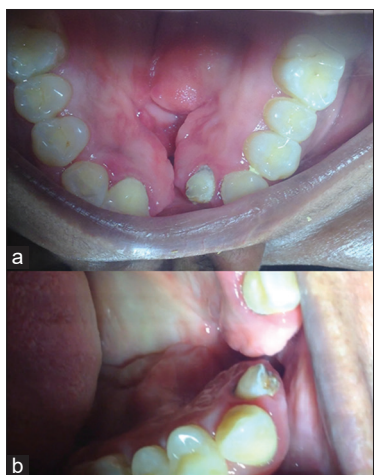


Figure 1: (a and b) Oronasal fistula



Figure 2: Final impression

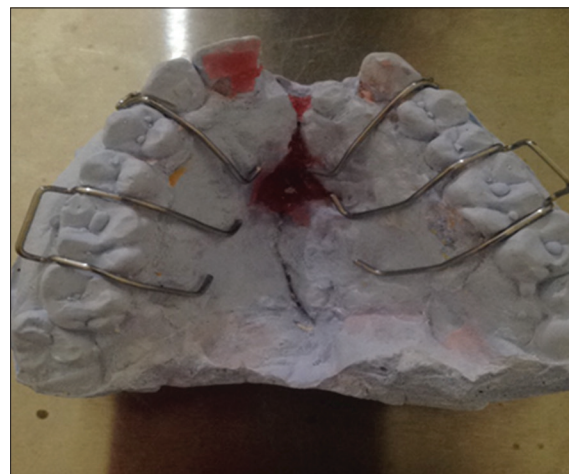

Figure 3: Master cast

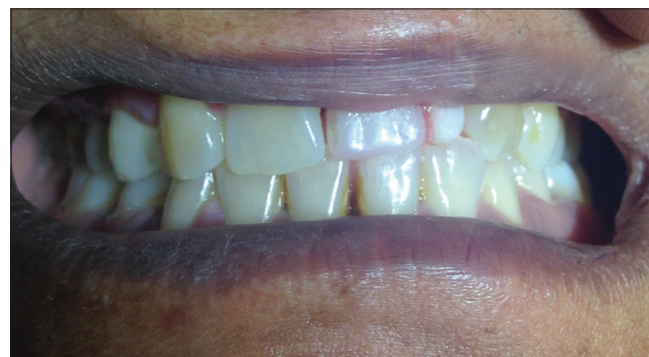

Figure 4: Wax try in

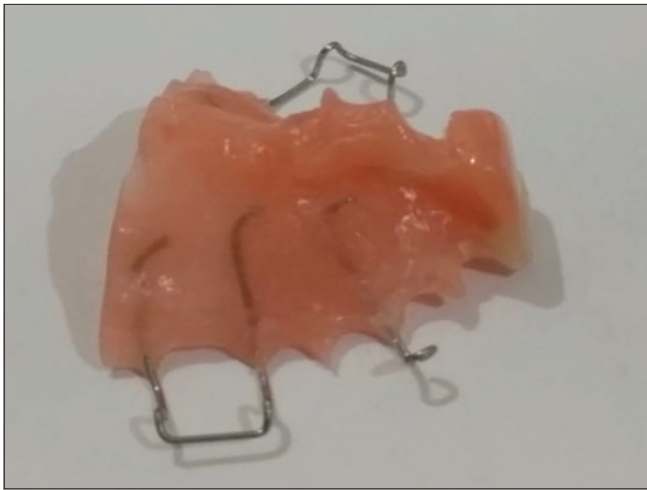


Figure 5: Obturator

prosthesis and psychologically the patient benefited by improved esthetics and speech. Recall appointments were scheduled for 1 week, 1 month, and 3 months.

DISCUSSION

Prosthetic treatment plays a major role in the rehabilitation of cleft lip, and palate patients for successful rehabilitation of such patients, a team approach of concerned specialist with phase wise, unanimous, and systematic treatment plan are essential. Prosthetic rehabilitation of these patients is usually around the age of 20, before which the patient will be treated for surgical primary closure, for alignment of teeth and finally for the replacement of missing teeth and obturation of the defect.

Obturator is an unmerited gratuitous treatment to surgical inevitableness. Common complication of cleft palate surgical repair observed in different studies is palatal fistula and to correct sequel of the surgery which is force majeure.

Advantages of the obturator are though the prosthesis. Retention and stability of the prosthesis are improved due to the attachment; size of the prosthesis was minimized with reduced palatal coverage where the patient had normal proprioception and taste perception. Patients comfort is enhanced.

A removable obturator or any other type of prosthetic treatment it may have own merits and demerits but on one of most important merit and foremost goal of any general dentist, prosthodontist or maxillofacial prosthetic

expert should be that it provides a psychosocial confidence and comfort and improves quality of life which is intangible income to one own self and we could use that and have in our lifetime to time and this is the way can give back to society. As such I believe there is nothing we are giving back we are just too small for that we are just instrumental part of big chaos if we are not using to our development than someone will and that only counts in the end with this noble profession that we are in.

CONCLUSION

Fabrication of the removable prosthesis, obturator attached to it is a time consuming, labor intensive and artistic job. The art of replacing missing teeth, the defect has been carried out for many years. Surgical reconstruction was not possible in this case and needed prosthetic rehabilitation. The technique has presented which was a removable type of prosthesis. The obturator was lightweight which was attached to the removable part of prosthesis. This promotes the physical and psychological healing for the patient and improved the esthetics. Thus, the accumulation of positive effect with psychological confidence and comfort as a result of the use of prosthesis for an oronasal fistula has undoubtedly improved the quality of life of the patient.

REFERENCES

1. Ankola AV, Nagesh L, Hedge P, Karibasappa GN. Primary dentition status and treatment needs of children with cleft lip and/or palate. *J Indian Soc Pedod Prev Dent* 2005;23:80-8.
2. Cohen SR, Kalinowski J, La Rossa D, Randall P. Cleft palate fistulas: A multivariate statistical analysis of prevalence, etiology, and surgical management. *Plast Reconstr Surg* 1991;87:1041-7.
3. Parwaz MA, Sharma RK, Parashar A, Nanda V, Biswas G, Makkar S. Width of cleft palate and postoperative palatal fistula—do they correlate? *J Plast Reconstr Aesthet Surg* 2009;62:1559-63.
4. Smith DM, Vecchione L, Jiang S, Ford M, Deleyiannis FW, Haralam MA, et al. The Pittsburgh fistula classification system: A standardized scheme for the description of palatal fistulas. *Cleft Palate Craniofac J* 2007;44:590-4.
5. Inman DS, Thomas P, Hodgkinson PD, Reid CA. Oro-nasal fistula development and velopharyngeal insufficiency following primary cleft palate surgery—an audit of 148 children born between 1985 and 1997. *Br J Plast Surg* 2005;58:1051-4.
6. James IE, Mohamed A. A fixed removable partial denture for cleft palate patients. *J Prosthet Dent* 1975;34:286-91.
7. Mazaheri M. Prosthetics in cleft palate treatment and research. *J Prosthet Dent* 1964;14:1146-58.