

## CASE REPORT

# Replacement of Missing Teeth and Restoration of Endodontically Treated Teeth Using Fiber-Reinforced Composite Resin - A Series of Case Reports

Neelam Vijaywargiya<sup>1</sup>, Suparna Ganguly Saha<sup>2</sup>, Manish Verma<sup>3</sup>, Mainak Kanti Saha<sup>4</sup>

## ABSTRACT

The loss of anterior teeth can be traumatic to the patient; both psychologically and socially. Various treatment modalities have been considered for the rehabilitation of such mutilated dentition. Conventional fixed partial dentures or implant supported prosthesis are often the treatment of choice. Fiber-reinforced composite (FRC) resins, however, serve as an interim immediate, minimally-invasive, reversible, single visit, and cost-effective alternative for anterior tooth replacement. The present case report discusses the successful replacement of an anterior edentulous space using FRC.

**Keywords:** Everstick, FRC, IPN

**How to cite this article:** Vijaywargiya N, Saha SG, Verma M, Saha MK. Replacement of Missing Teeth and Restoration of Endodontically Treated Teeth Using Fiber-Reinforced Composite Resin - A Series of Case Reports. *Int J Prev Clin Dent Res* 2018;5(1):192-196.

**Source of support:** Nil

**Conflicts of interest:** None

## INTRODUCTION

Modern restorative and rehabilitative dental procedures have evolved into an amalgamation of biologically, functionally, and esthetically oriented new materials along with new age dental techniques. This has enabled the operator to make innovative decisions in clinical practice that is at par with the patient's expectations.

Over the past few years, the development of fiber-reinforced composite (FRC) has offered the dental

profession a variety of clinical applications. It provides the possibility of fabricating resin-bonded, esthetically acceptable and metal-free tooth restorations for immediate teeth replacement. This material can be directly processed intraorally, shows good adherence to natural teeth and has with adequate strength to withstand masticatory forces. Furthermore, prefabricated FRC posts, composed of glass fibers embedded in a polymer matrix, can be considered as viable alternatives to metal post systems in the restoration of endodontically treated teeth. This case series discusses the various applications of FRC material both as a crown and bridge material and a post system.

## CLINICAL CASE REPORTS

### Case 1

A 22-year-old female patient reported to the Department of Conservative Dentistry and Endodontics having a chief complaint of loss of anterior tooth with an urge to immediately replace a missing upper right central incisor. She presented a history of trauma 1 year back. On clinical examination, the maxillary left central incisor was found to be missing with loss of buccal cortical plate. The anterior teeth presented a normal horizontal and vertical overlap, a Class I molar relationship with a canine guided occlusion. All the possible treatment modalities were explained to the patient. After discussion, it became clear that the placement of an implant for the replacement of the missing tooth had to be ruled out due to the availability of limited time. The fabrication of a conventional fixed partial denture was avoided as the patient did not want mutilation of adjacent healthy teeth which would result from tooth preparation as warranted by conventional fixed prostheses at the present juncture. Options for the conventional treatment with implants or crown-retained FPDs remained open for the future. After obtaining written informed consent from the patient, directly made FRC FPDs (Stick Tech Ltd, Turku, Finland) was chosen as the treatment of choice to provide immediate acceptable esthetics, preserve tooth substance, and postpone definitive but more invasive treatments. The treatment was completed in a single appointment. A sufficient overjet and overbite allowed

<sup>1,3</sup>Tutor, <sup>2,4</sup>Professor and Head

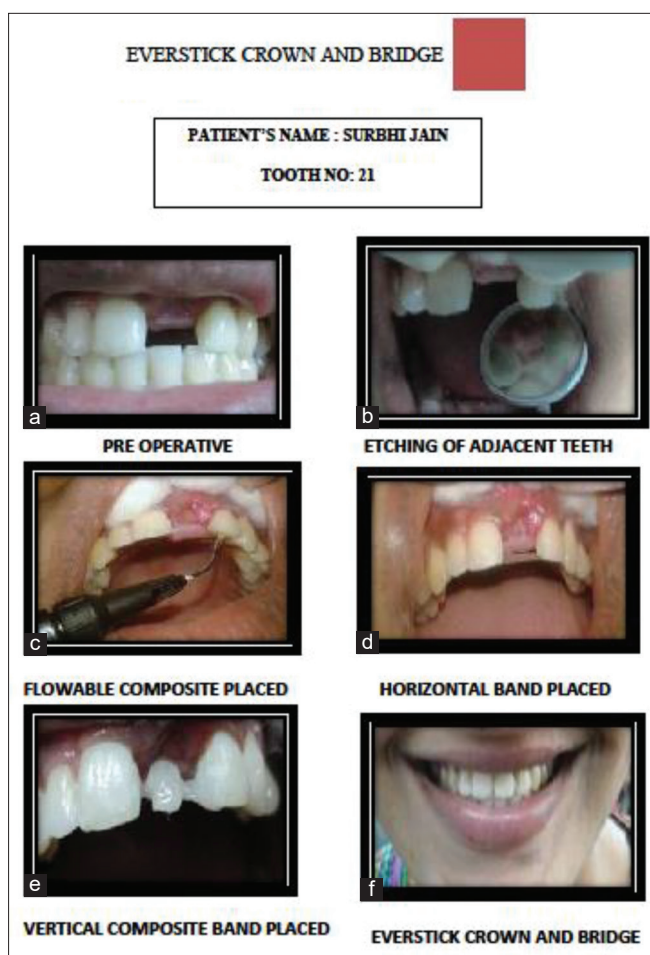
<sup>1</sup>Department of Conservative Dentistry and endodontics, Government College of Dentistry, Indore, Madhya Pradesh, India

<sup>2</sup>Department of Conservative Dentistry, College of Dental Science, Rau, Indore, Madhya Pradesh, India

<sup>3</sup>Department of Periodontics, Government College of Dentistry, Indore.

<sup>4</sup>Department of Prosthodontics, College of Dental Science, Rau, Indore

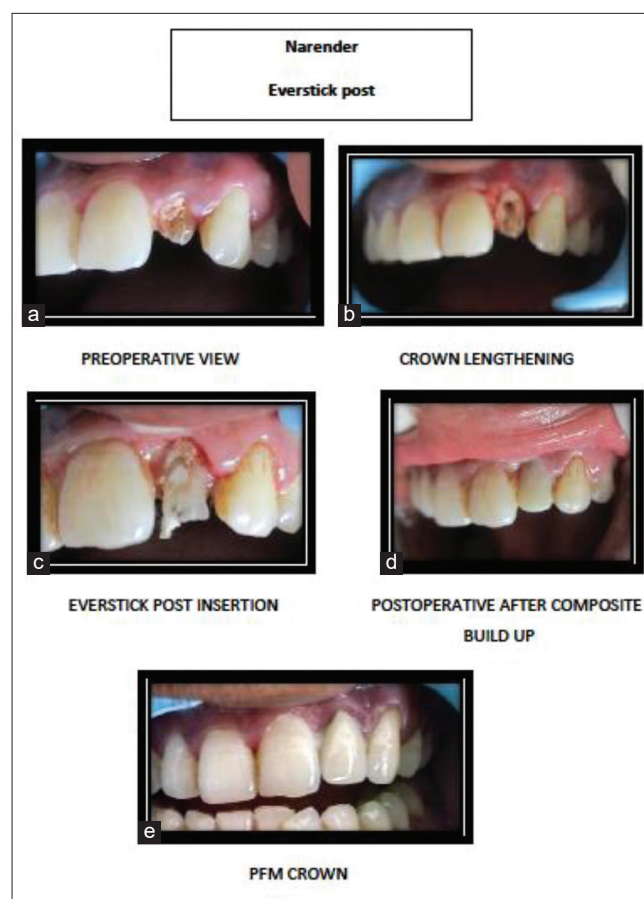
**Corresponding Author:** Dr. Neelam Vijaywargiya, 8, Chameli Park Colony, Near Goyal Nagar, Indore - 453 331, Madhya Pradesh, India. Phone: +91-9826046085. e-mail: neelam\_vijaywargiya@yahoo.co.in



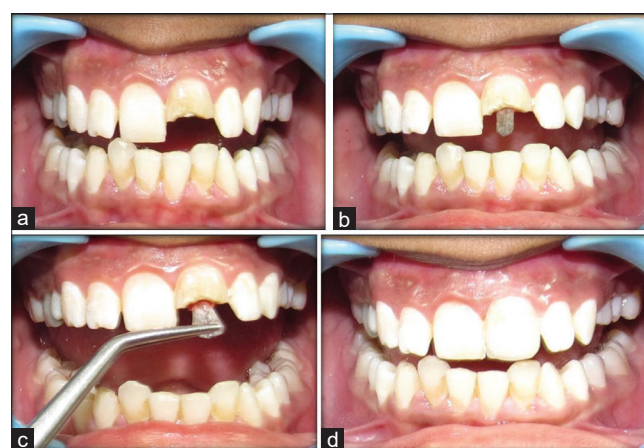**Figure 1:** (a) Pre-operative, (b) etching of adjacent teeth, (c) flowable composite placed, (d) horizontal band placed (e) vertical composite band placed, (h) everstick crown and bridge

the placement of the FRC framework on the palatal aspects of the abutment teeth. Consequently, no cavity preparation for receiving vertical support for the bridge was needed. Proper protocol for isolation was followed. The space between the teeth adjacent to the edentulous space was measured, and a bundle of pre-impregnated EverStick glass fibers was cut to the required length to adapt along the palatal surface of teeth 11 and 22. Care was taken to prevent prior exposure of the bunch fiber to visible light till it was ready for adaptation to the adjacent teeth for the final bonding.

After application of acid etchant (37% phosphoric acid gel) for 15 s, the etched surface was rinsed thoroughly and gently air dried [Figure 1(a)]. Adhesive resin was applied according to the manufacturer's instructions [Figure 1(b)] (Scotchbond multipurpose adhesive, 3M ESPE, USA) to the tooth surface. Flowable composite resin (Stick Flow, Stick Tech Ltd, Turku, Finland) was applied on the bonding surfaces before placing the resin impregnated fibers (EverStick). The flowable composite [Figure 1(c)] was light-cured after the fibers were pressed tightly against the tooth surface using a

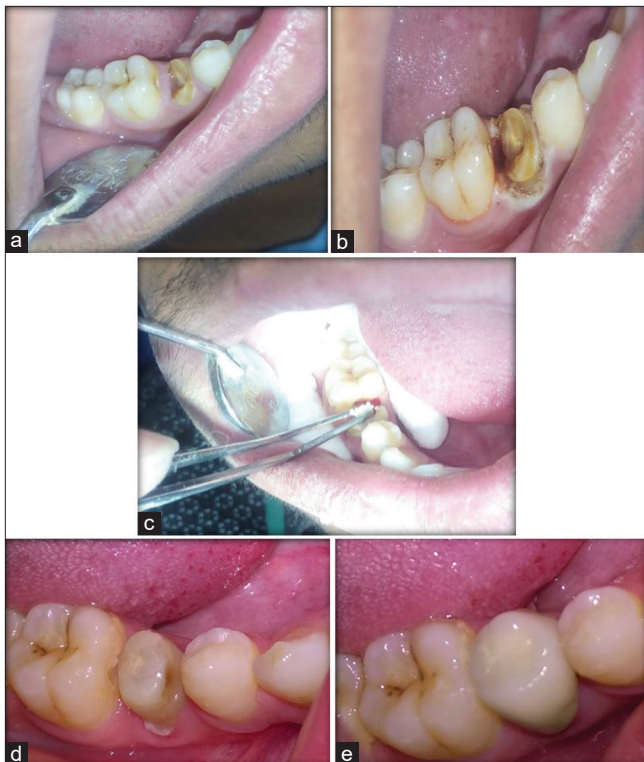

**Figure 2:** (a) preoperative view, (b) crown lengthening, (c) everstick post insertion, (d) post operative after composite build up, (e) PFM crown



**Figure 3:** (a) Pre-operative, (b) with EverStick post, (c) Shaping of post, (d) post-operative

transparent silicone package (mold) of the fibers. The resin impregnated fibers were light cured initially through the silicone mold. The purpose of the flowable composite was to seal the space between the fibers and the enamel surface. The fiber framework was polymerized 2 times for 40 s each. The fiber framework was then fully covered with a thin layer of flowable composite resin, and the pontic was built up layer by layer



**Figure 4:** (a) Post-placement, (b) core build up, (c) PFM crown, (d) Pre-operative, (e) crown lengthning

using nanohybrid type particulate filler composite resin [Figure 1(d)]. Successful chemical bond between fiber framework and veneered composite was achieved by light curing. The shade of final veneered composite resin was selected using composite shade guide, and occlusion was carefully adjusted with articulating paper. The occlusion was adjusted carefully to avoid any primary or premature contacts [Figure 1(e)] both in centric and eccentric and also to prevent traumatic occlusal forces to the restored teeth [Figure 1(f)].

## Case 2

A 29-year-old male patient with a chief complaint of pain in the upper front tooth region reported to the Department of Conservative Dentistry and Endodontics. Clinical and radiographic examination revealed a grossly carious maxillary left lateral incisor with pulpal involvement and presence of minimal crown structure labially. Endodontic therapy followed by FRC post and metal-ceramic crown was planned for the tooth.

Endodontic treatment was performed following standard protocol [Figure 2(a)]. 10 days later, crown lengthening procedure was performed with the same tooth to expose sufficient coronal tooth structure [Figure 2(b)] necessary for adequate retention and resistance form for the post-endodontic restoration. Post space was created following standard protocol leaving 4–5 mm apical seal. The depth of the prepared canal was measured, and the

height of crown structure was estimated. The required length of fiber post was cut and removed from the silicone mold using tweezers and inserted into the canal ensuring a proper fit.

The root canal walls were etched with 37% phosphoric acid for 15 s, rinsed with water and dried using paper points. Subsequently, two consecutive coats of bonding agent (single bond 2, 3M ESPE, St Paul, MN, USA) were applied with a microbrush and air dried, and then light cured for 20 s. To fit with the diameter of the canal, an EverStick Post (Stick Tech Ltd, Turku, Finland) with a diameter of 1.2 mm was used. The post was inserted into the root canal to the appropriate depth, and the coronal section of the post was shaped to improve support for the crown, and then shortened to an appropriate length with sharp scissors.

Before cementation, a layer of light-curing resin adhesive (Stick Resin, Stick Tech Ltd, Turku, Finland) was applied to the surface of the post by gently blowing the surface of the post with dry, oil-free air, and curing with light for 10 s. After further checking the fit of the glass fiber post inside the root canal, the post was further light cured for 20 s.

Post cementation was done using low viscosity dual cure 3M™ RelyX™ resin cement following the manufacturer's instructions. Core build-up was done using composite resin core build-up material Paracore [Figure 2(c)] (Paracore, Coletene/Whaledent Inc., Cuyahoga Falls, OH, USA). Following this, the tooth was prepared to receive a metal-ceramic crown. The crown was fabricated and cemented as per accepted clinical protocol [Figure 2(d)].

## Case 3

An 19-year-old female patient reported to the Department of Conservative Dentistry and Endodontics with a chief complaint of acute pain in the upper left front tooth. Clinical examination revealed a fracture in the her maxillary left central incisor tooth (21) at the level of the cement-enamel junction. The tooth [Figure 3(a)] was treated endodontically (obtured with gutta-percha and resin sealer) following a standard protocol followed by crown lengthening. Thereafter, the gutta-percha was removed from coronal two-third of the root canals using Gates drills (Antaeos, VDW GmbH, Munchen, Germany) leaving 5 mm of gutta-percha in the apical third. The post space was prepared following the general principles using peeso reamers.

Thereafter, the tooth was restored using FRC post and composite core following a similar protocol as case 2 [Figure 3(b,c,d)].



## Case Report 4

A 21-year-old male patient reported to the department with a chief complaint of badly decayed tooth in lower right posterior region. On clinical examination, lower right mandibular premolar (35) was found to be carious with loss of about 60% of its coronal structure [Figure 4(a)]. Radiographic evaluation revealed carious lesion involving pulp.

The treatment plan for the patient included endodontic management of the premolar along with crown lengthening which was followed by post and core using [Figure 4(b)] (EverStick post) followed by PFM crown [Figure 4(c,d,e)].

## DISCUSSION

In the restoration or replacement of traumatized or missing anterior teeth, both esthetic and mechanical considerations should be taken into account. For fractured anterior teeth, there are several treatment alternatives including composite resin restoration and prosthetic repair. However, a combination of glass fiber as post and composite restorations can serve as a suitable alternative since they require lower chair time and minimal tissue removal.<sup>[1]</sup> FRC resins can also serve as immediate, minimally-invasive, reversible, single visit, and cost-effective alternative for anterior tooth replacement.<sup>[2]</sup> FRC, made up of glass fibers, is the only existing esthetically acceptable material, which can be processed directly in the mouth to form the framework of a bridge, simultaneously adhering to the adjacent teeth with adequate strength to withstand the masticatory forces.

EverStick™, a FRC material is made from unidirectional glass fibers and a polymer/resin gel matrix. The polymer/resin gel matrix holds the individual glass fibers in a bundle, which facilitates handling of the fiber bundle. The fiber bundle is flexible and tacky, which allows its easy and reliable bonding to teeth. This design makes the glass fibers flexible but prevents the fraying of the material from within the matrix when adapted to a surface.<sup>[3]</sup>

Fiber-reinforced posts are currently an acceptable treatment modality in the restoration of endodontically treated teeth having little remaining coronal tooth structure. These posts are preferred over metal posts as they have overcome the inherent disadvantage of metal posts which include root cracking and subsequent root fracture. The fiber-reinforced posts possess a high tensile strength and an elastic modulus similar to that of dentine, thus precluding the possibilities of root fracture in addition to having an esthetic appearance.<sup>[4]</sup> Previous studies have reported that EverStick posts have acceptable fracture resistance values ( $950.1 \pm 4.7$  N.)<sup>[5]</sup> This can be attributed to the Interpenetrating Polymer Network

(IPN) structure of the post that results in an interdiffusion bonding phenomenon, thus enabling the resin to penetrate the post along with the establishment of a strong bond to dentin through the resin cement. The interlocking of the resin cement into the IPN polymer matrix hence creates a strong bond after polymerization.

The EverStick crown and bridge fiber (Stick Tech Ltd., Finland) used in the present study consists of 4000 individual silanated E-glass fibers that are fully impregnated with resin. The fibers are locked to each other with linear polymers (PMMA) and cross-linking monomers (bis-GMA) to form unique and patented strong, esthetic and user friendly IPN structure. The IPN technology ensures a strong consistent bond due to both micromechanical and chemical adhesion between the EverStick fibers and the overlay composites, adhesives, or composite cement. The bond strength is based on the ability of the polymer matrix to partially dissolve in the resin used for bonding. The significance of this is that surfaces can be reactivated even after final polymerization. This reactivation dissolves linear polymers and forms new chemical bonds. The resin can also penetrate deeper into the fiber matrix which improves the micromechanical retention. With these crown and bridge fibers it is possible to produce a thin but strong, composite resin bonded bridge in a single visit. This prosthesis has been referred to as Resin Bonded FRC Fixed Partial Denture or FRC FPD.<sup>[6]</sup> These bridges show rigidity and flexural strength 7 times that of composite resin alone.<sup>[7]</sup> The flexural strength of Ever Stick fiber is considerably high (more than 700 MPa) when compared to previously used fibers like Rebond (200MPa).<sup>[8]</sup>

There is limited clinical research available on the FRC composites; however, based on the results currently available, it is reasonable to expect FRC restorations to have good longevity, especially with those made by the direct technique.

## CONCLUSION

FRC resin material has been shown to have satisfactory clinical results in a variety of clinical situations. However, long-term follow-up is required to assess the longevity of such restorations before establishing this treatment protocol in clinical dentistry routinely.

## REFERENCES

1. Baranwal HC, Baranwal AK, Srivastava A. Management of fractured maxillary incisor with bio dentine, ever stick glass fiber as post and composite resin. *Endodontology* 2015;27:57-61.
2. Khetarpal A, Talwar S, Verma M. Creating a single-visit, fibre-reinforced, composite resin bridge by using a natural tooth pontic: A viable alternative to a PFM bridge. *J Clin*

- Diagn Res 2013;7:772.
3. Garoushi S, Lassila L, Vallittu PK. Resin-bonded fiber-reinforced composite for direct replacement of missing anterior teeth: A clinical report. *Int J Dent* 2011;2011:845420.
  4. Lamichhane A, Xu C, Zhang FQ. Dental fiber-post resin base material: A review. *J Adv Prosthodont* 2014;6:60-5.
  5. Vats A, Srivastava S, Kukreja M, Chhabra HS. High strength and bonding achieved with new flexible everstick posts: A case report. *Endodontology* 2016;28:188-91.
  6. Kumar KP, Nujella SK, Gopal SS, Roy KK. Immediate esthetic rehabilitation of periodontally compromised anterior tooth using natural tooth as pontic. *Case Rep Dent* 2016;2016:8130352.
  7. Goldberg AJ, Freilich MA. An innovative pre-impregnated glass fiber for reinforcing composites. *Dent Clin North Am* 1999;43:127.
  8. Davis P, Melo LS, Foxton RM, Sherriff M, Pilecki P, Mannocci F, et al. Flexural strength of glass fibre-reinforced posts bonded to dual-cure composite resin cements. *Eur J Oral Sci* 2010;118:197-201.